

**Case report****A Case Of Pulmonary Non Tuberculous mycobacteria Mimicking Pulmonary Tuberculosis*****Amit Goyal^a, N C kajal^b, Amanpreet Kaur^a**^aJunior Resident, Department of Chest and TB, GMC Amritsar.^bProfessor, Department of Chest and TB, GMC Amritsar.

ARTICLE INFO

Keywords:*Nontuberculous mycobacterium (NTM)*
Mycobacterium abscessus

ABSTRACT

Nontuberculous mycobacteria (NTM) are naturally-occurring organisms found in water, soil and wild animals. They are harmless to most people but when a person inhales the organism from the environment NTM led to lung infection. Most people don't become ill except for some susceptible individuals, a slowly progressive and destructive disease can occur. Chronic respiratory disease is a strong risk factor. Here, we report a case of pulmonary nontuberculous mycobacterial (NTM) infection with *M. abscessus*. This case highlights the diagnostic confusion which occurs when persistent sputum Acid- Fast Bacilli (AFB) smears are positive, but Nucleic acid amplification test is negative.

© Copyright 2010 BioMedSciDirect Publications IJBMR - ISSN: 0976:6685. All rights reserved.

1. Introduction

Historically, pulmonary infection due to mycobacterium has been well known as tuberculosis. Later, other mycobacterium species were identified, they are referred to as atypical mycobacterium, mycobacterium others than tuberculosis (MOTT) or nontuberculous mycobacterium (NTM). They are aerobic, non-motile organisms that appear positive with acid-fast alcohol stains and are ubiquitous in the environment with the heaviest concentration found in soil and water [1]. They are most commonly associated with pulmonary infections. There has been an increase in the incidence of pulmonary infections caused by NTM in recent years, and this is an emerging public health concern. The epidemiologic characteristics (especially incidence) of NTM pulmonary disease are difficult to estimate [2]. NTM represent over 180 different species and subspecies, most of which do not seem to cause human disease except in individuals who are susceptible. NTM been further divided into slow- and rapid growing groups. The most common of the slow-growing is *M. avium* complex (MAC) and from rapid-growing *M. abscessus* [1].

Many people with NTM lung disease have another underlying lung problem like COPD, bronchiectasis, or lung damage due to previous infections such as tuberculosis [3].

In this case bronchiectasis is present as the underlying lung problem.

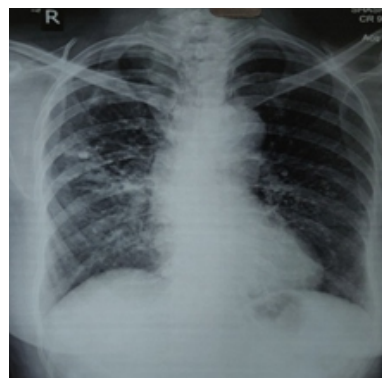Case Report

We report a case of 60year old female presented with complaint of Breathlessness, Cough with expectoration, Haemoptysis since 5 months along with history of low grade fever, Night sweats and loss of appetite. There was no history of Chest Pain And Weight Loss. On examination Patient was moderately built Bp-110.70 RR-28 There was no pallor, clubbing, cyanosis, Lymphadenopathy or pedal edema.

Respiratory system examination revealed right side interscapular and infrascapular coarse crepts. Other systems were normal.

Further serological investigation normal leucocyte count, ESR-60mm. Renal and Liver functions were within normal limits. HIV serology was non reactive.

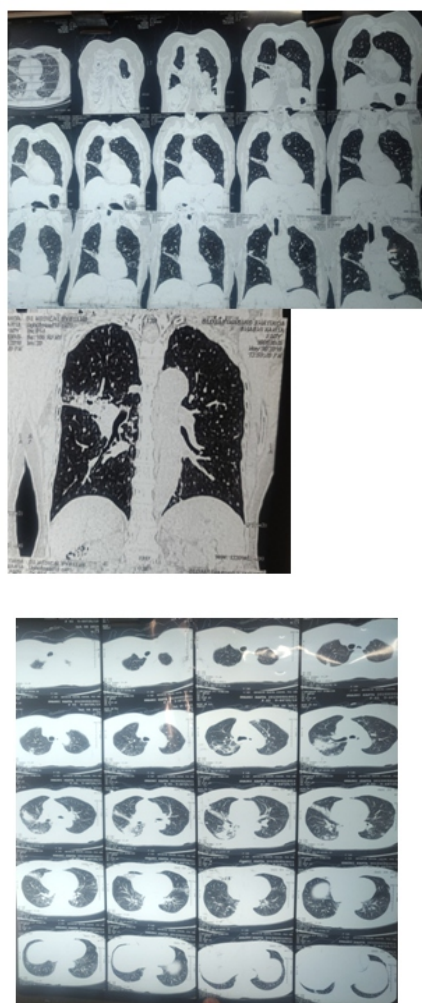
Chest -X ray (Fig-1) showing bronchiectatic changes in right middle zone

Fig-1* Corresponding Author : **Dr Amit Goyal**Junior Resident, Department of Chest and TB,
Govt medical college, Amritsar, Circular Road, Amritsar,
Punjab-143001, India.
Email- goyal5757@gmail.com

Her sputum examination for AFB came out to be 1+ .However Gene Xpert test for Mycobacterium Tuberculosis was negative that is MTB not detected on CBNAAT but culture showed growth of Non tuberculous Mycobacteria identified as Mycobacterium abscessus.

CECT Chest showed thick walled cavity with multiple foci of granulomatous calcification with surrounding fibrosis and bronchiectasis in posterior segment of right upper lobe with adjacent pleural thickening and in superior segment of right lower lobe.Features suggestive of Koch pathology with possible active infection.

FIG 2,3,4



The decision to treat was guided by the positive CT Findings and recurrent positive AFB growth So this patient diagnosed with a case of non mycobacterium tuberculosis.

The M. abscessus isolate was found to be susceptible to amikacin, clarithromycin, azithromycin, imipenem/cilastatin and ciprofloxacin.This patient is initiated on inj.Amikacin 15 mg/kg/day,Rifampicin 600mg/day,Ethambutol 800mg/day,Clarithromycin 50mg/day for management of Mycobacterium abscessus.

Discussion

Pulmonary infections with NTM occur in patients with or without predisposing conditions and recognition of this disease is delayed due to its indolent nature[4]. Symptoms & signs are non-specific. Fever & weight loss occur less frequently than in patients with typical tuberculosis. The American Thoracic Society/Infectious Diseases Society of America (ATS/IDSA) guidelines recommended that the diagnosis of NTM pulmonary disease should be based on clinical, radiographic, and microbiologic findings [5] the prevalence of NTM infection has increased worldwide in recent decades [6].The most common species causing disease is called Mycobacterium avium complex. The next most common is Mycobacterium abscessus complex and Mycobacterium kansasii. Species- and subspecies-level identifications are important because of antibiotic susceptibility and different outcomes of therapy depending on the isolated subspecies.

The incidence of NTM increases with the age. In the patients over 65 years of age the prevalence is 47 per 100.000 years and women are found more likely to suffer from NTM than men [7].

NTM causes symptoms similar to a chronic and non-resolving pneumonia. Common symptoms include:

- cough with sputum production
- tiredness (fatigue)
- fever
- coughing up blood (hemoptysis)—a late sign of illness
- weight loss.

Typically NTM pulmonary disease is treated with three or more antibiotics until sputum cultures have been negative for 12 months. Commonly used antibiotics include macrolides, ethambutol, rifampicins, aminoglycosides, fluoroquinolones, imipenem and linezolid.

Laboratory results in this patient showing persistent sputum for AFB positive & Gene Xpert for M. Tuberculosis negative raised a diagnostic dilemma both in terms of isolation of the patient & treatment involved[9]. Final diagnosis of M. abscessus infection was made as the Sputum specimen confirmed growth on culture.

Conclusion

Lung infections due to M. abscessus are extremely difficult to treat. Many Physicians misdiagnosed the NTM as Pulmonary Tuberculosis. So it is important to consider NTM as a differential diagnosis of Non resolving pulmonary infection. The precise differentiation between types and subtypes of NTM is necessary because of different therapy recommendations and prognosis.

Conflict of Interest

Nil

References:

- [1] Johnson MM, Odell JA. Nontuberculous mycobacterial pulmonary infections. Journal of thoracic disease. 2014 Mar;6(3):210.
- [2] Stout JE, Koh WJ, Yew WW. Update on pulmonary disease due to non-tuberculous mycobacteria. International Journal of Infectious Diseases. 2016 Apr 1;45:123-34.

- [3] Andréjak C, Nielsen R, Thomsen VØ, Duhaut P, Sørensen HT, Thomsen RW. Chronic respiratory disease, inhaled corticosteroids and risk of nontuberculous mycobacteriosis. *Thorax*. 2013 Mar 1;68(3):256-62.
- [4] Prince DS, Peterson DD, Steiner RM, Gottlieb JE, Scott R, Israel HL, Figueroa WG, Fish JE. Infection with *Mycobacterium avium* complex in patients without predisposing conditions. *New England Journal of Medicine*. 1989 Sep 28;321(13):863-8.
- [5] Griffith DE, Aksamit T, Brown-Elliott BA, Catanzaro A, Daley C, Gordin F, Holland SM, Horsburgh R, Huitt G, Iademaro MF, Iseman M. An official ATS/IDSA statement: diagnosis, treatment, and prevention of nontuberculous mycobacterial diseases. *American journal of respiratory and critical care medicine*. 2007 Feb 15;175(4):367-416.
- [6] Prevots DR, Marras TK. Epidemiology of human pulmonary infection with nontuberculous mycobacteria: a review. *Clinics in chest medicine*. 2015 Mar 1;36(1):13-34.
- [7] Adjemian J, Olivier KN, Seitz AE, Falkinham III JO, Holland SM, Prevots DR. Spatial clusters of nontuberculous mycobacterial lung disease in the United States. *American journal of respiratory and critical care medicine*. 2012 Sep 15;186(6):553-8.
- [8] Nucleic acid amplification tests in the diagnosis of TB. *MMWR Morbidity and Mortality Weekly Report* 2009; 58:7