




Contents lists available at BioMedSciDirect Publications

International Journal of Biological & Medical Research

Journal homepage: www.biomedscidirect.com



Case Report

Giant Hydronephrotic Kidney Masquerading as Bowel Obstruction: A Rare Case Report and Review of Literature

Dr.Ambikavathy.M^a, Dr.Krishna Shetty.M.V^b, Dr.Bhaskaran.A^c, Dr.Kumar.S^d.

^aAsst Prof in General Surgery, Sri Devaraj Urs Medical College and Research Centre, Tamaka, Kolar, Karnataka, India.

^b Professor and H.O.D, Dept of Urology, Sri Devaraj Urs Medical College and Research Centre, Tamaka, Kolar Karnataka, India.

^c Professor and H.O.D, Dept of General surgery, Sri Devaraj Urs Medical College and Research Centre, Tamaka, Kolar Karnataka, India.

^dAsst Prof in General Medicine, Sri Devaraj Urs Medical College and Research Centre, Tamaka, Kolar Karnataka, India.

ARTICLE INFO

Keywords:

Hydronephrosis
Giant
Abdominal cyst
Bowel obstruction

ABSTRACT

Unilateral hydronephrosis is swelling of one kidney due to backup of urine. Unilateral hydronephrosis occurs in approximately 1 in 100 people. Any kidney harbouring 1000cc or more of fluid is considered as massive/giant hydronephrosis. Despite the frequency in use of prenatal ultrasonography, giant hydronephrosis may still be seen in adult population. We report a rare case of an adult male patient aged 30yrs with giant hydronephrosis of the right kidney, who presented with symptoms of subacute bowel obstruction. Literatures have reported very few cases presenting with this symptom. The patient underwent an uneventful retroperitoneal right total nephrectomy and the histopathology reported hydronephrosis of right kidney with pyelonephritic changes. The patient is symptom free till date and has normal renal functions.

© Copyright 2010 BioMedSciDirect Publications IJBMR -ISSN: 0976:6685. All rights reserved.

1. Introduction

Giant hydronephrosis has been defined as a kidney that harbours over 1000 ml of urine in the sac.[1,6] It is also defined as that which occupies a hemiabdomen, which meets or crosses the midline and which is at least 5 vertebrae in length.[7] (Hoffman, 1948; Papin-quoted by sterling).

Yang et. al (1958) opined that the term giant hydronephrosis should be used only when the contents of the sac equalled to the average daily urine output for that age.[1]

With the widespread use of ultrasonography most of the hydronephrosis are diagnosed much earlier before it is large enough to produce a visible swelling. Rarely hydronephrosis presents as an intraabdominal mass simulating a subacute intestinal obstruction.[11]

We report a rare case of a rapidly progressive right giant hydronephrotic kidney in an adult male patient aged 30 yrs, who clinically presented with features of bowel obstruction.

2. Case illustration

A 30 years old adult male patient presented to our hospital with rapidly progressive abdominal distension, constipation, nausea and occasional vomiting after taking food for a duration of two months. He did not have pain abdomen or any urological complaints. He denied trauma to the abdomen. He did not have fever or loss of weight. No similar symptoms of abdominal distention in the past and no history of previous abdominal surgery.

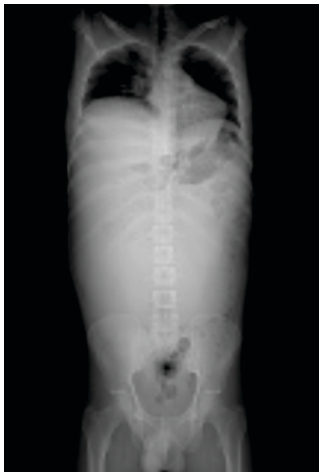His vitals were BP-130/80, pulse rate-90/min, RR-22/min and he was afebrile.

On local examination: abdomen was grossly distended and non tender, small bowel peristalsis was seen suggestive of bowel obstruction, bowel sounds were exaggerated, fluid thrill could be elicited, there was no shifting dullness, a tensely cystic mass 20x30 cms was palpable in the right hemiabdomen crossing the midline towards the left iliac region, per rectal examination revealed a roomy rectum suggestive of obstruction. Examination of the other systems was unremarkable.

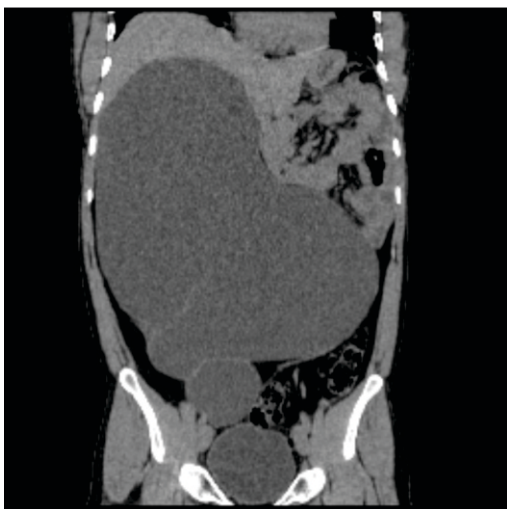* Corresponding Author : Dr.Ambikavathy.M

With the above findings a clinical diagnosis of retroperitoneal cyst with mechanical bowel obstruction was made. The patient was investigated. His routine blood parameters were within normal limits, serum creatine was 0.9mg/dl. An erect abdomen x-ray showed distended bowel loops with multiple air fluid levels pushed to the periphery on the left of abdomen confirming obstruction. Fig:1. Ultrasonography showed a huge grade 4 right hydronephrotic(multiloculated cystic) kidney measuring 24 x 27 x 30 cms with normal left kidney. A contrast enhanced CT abdomen and pelvis reported- a massive hydronephrosis of right kidney, the sac measuring 24 x 26.9 x 35 cms with gross enlargement of the pelvis to the left and displacement of liver and gall bladder and pressure effect on small bowel loops, study suggestive of right congenital pelviureteric junction obstruction.(fig:2,3,4)

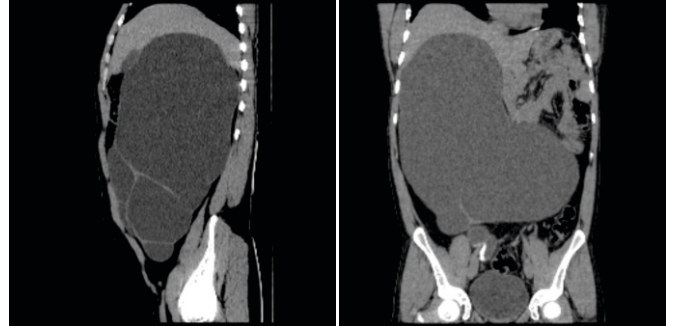
Fig 1: X ray erect abdomen showing ground glass appearance with bowel shadows towards the periphery on the left.



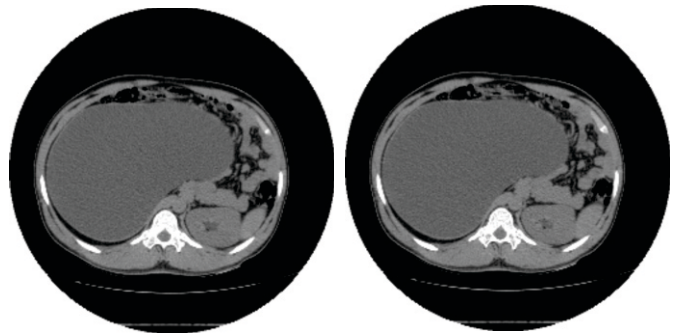
Figs 2 : showing axial CT Abdomen with massively enlarged right kidney with normal left kidney.



Figs 3- CT abdomen showing massive hydronephrotic right kidney crossing the midline with septae.



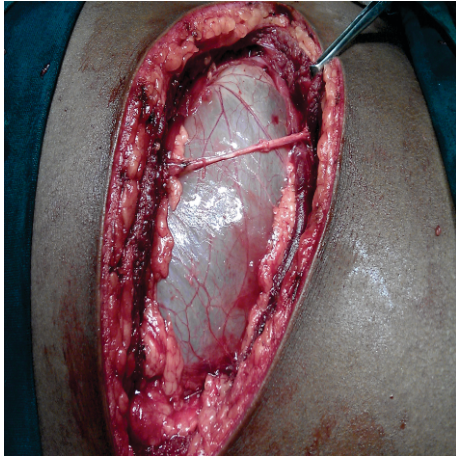
Figs 4- cross section CT abdomen showing massively enlarged right kidney with pressure effect over the bowels.



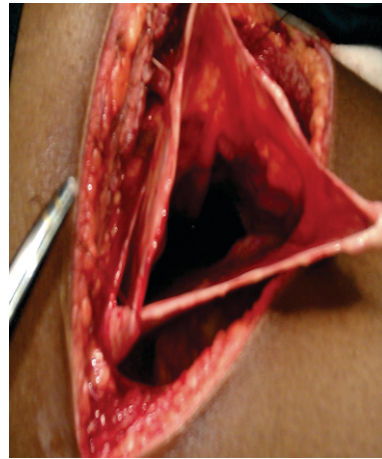
The urologists consultation was sought. The patient was subjected to a intravenous pyelogram which revealed a non visualization of the affected unit even after 24 hrs (non functioning right kidney) with a normal left kidney. With a final diagnosis of giant right hydronephrotic non functioning kidney with mechanical bowel obstruction the patient was planned for elective surgery.

The patient was a known case of allergic bronchitis therefore physicians opinion was taken for the fitness to surgery and advise. The patient successfully underwent right total retroperitoneal nephrectomy. The intra operative findings was - a grossly enlarged kidney with thinned out cortex. Perinephric extravasation of fluid was noted mimicking a pseudo cyst. The enlarged kidney extended from the right diaphragm to the pelvic brim and from right loin crossing to the left of midline towards the left iliac fossa touching anterior and posterior abdominal wall. The sac was opened up and fluid aspirated to facilitate further dissection. The sac contained 15 litres of clear fluid, pelvis was grossly dilated, black sediments was noted in the sac, right ureteropelvic junction could not be defined, the ureter was cord like suggesting pelviureteric junction obstruction. The lower pole of the kidney had some compressed residual renal tissue.(op.figs:3,4,5,6,7,8,9)

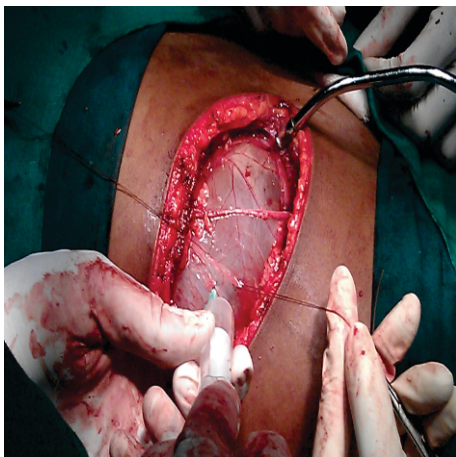
Op Fig 1: Hydronephrotic kidney seen protruding through the operative wound.



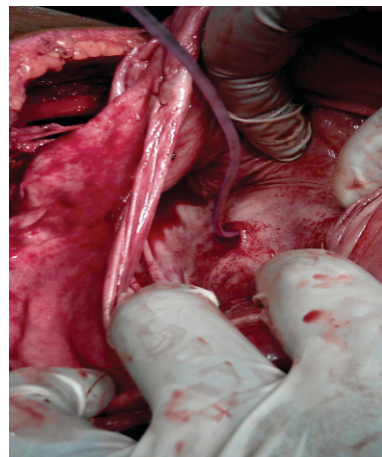
Op Fig 4- showing opened out hydronephrotic sac



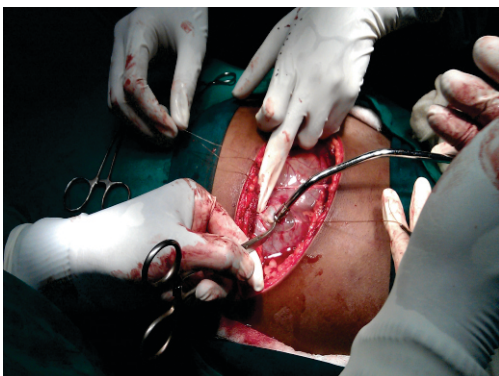Op Fig2 : fluid being aspirated from the Hydronephrotic kidney.



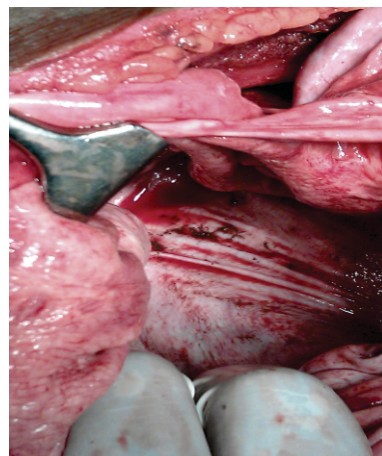
Op.Fig 5- demonstration of PUJ obstruction with the feeding tube being passed in to the ureter.

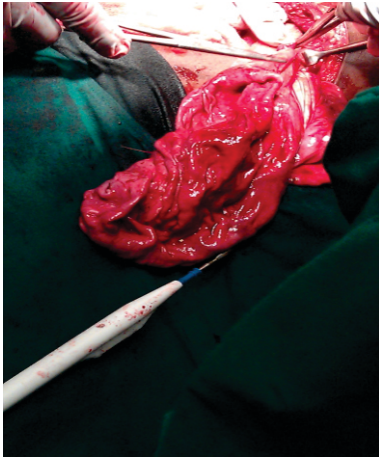
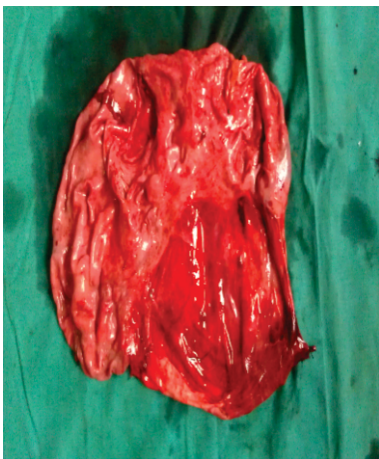
Op.fig3-fluid being sucked out from the sac hydronephrotic sac.



Op.fig6- showing black sediments in sac.



op.Fig 7- The hydronephrotic sac brought out.**Op.Fig 8- Total Nephrectomy specimen.**

The histopathology examination vide no: B-1177-11 reported-features of chronic hydronephrosis of kidney with pyelonephritic changes.

Postoperatively the patient recovered well and was discharged on seventh postop day. The subsequent follow up of the patient revealed normal renal function tests and the patient is free of gastro intestinal symptoms till date.

3.Discussion

The largest hydronephrotic sac with 115 litres of fluid was recorded by glass(1746)[8] in an autopsy report on a 22 year old women. Tombori et al (1968)[2] reported the second largest case of giant hydronephrosis with 52 litres of fluid and reported that out of 61 cases 33 were misdiagnosed as ascites and paracentesis was done in 12 cases. Our patient had 15 litres of fluid in the giant sac and weighed 13 kilograms(preop patients weight-postop weight)

The decline in incidence of erroneous diagnosis in recent days is due to the availability of expert sinologists.[9] However ultrasound findings are not characteristic of hydronephrosis as in the diagnosis of hydronephrosis at an earlier stage.[3]

The interesting feature of the disease in our case is the rapid progression, within two months the patient had developed massive hydronephrosis of this degree. This kind of rapid progression of the disease could not be found in the available literature. Weil et al (1862) have described similar abdominal swelling in eight months.⁵ Most of the cases of giant hydronephrosis reported earlier had a slowly progressive disease with chronicity.[2,10]We feel that ischaemic changes due to pressure effect in the residual parenchyma, could have lead to the rapid aggravation of hydronephrotic changes in the affected kidney. In experimental animals ureteric obstruction in ischaemic kidney has been reported to produce rapidly progressive hydronephrotic changes.[4]

The differential diagnosis of a giant renal cysts(<15cms in diameter) though rare as compared to giant hydronephrosis, has to be kept in mind, especially in a non functioning unit.[11] However it is confirmed at surgery.

Such large cystic renal swellings are known to present with abdominal mass or distension, fever, hypertension, sepsis, flank pain, and haematuria.[9] Patients presenting with features of intestinal obstruction is an exceptionally rare entity and largely unreported event.[11] such a rare feature was seen in our case and only a few have been reported in literature so far, and this is the reason for us in reporting it.

4.Conclusion

Giant hydronephrosis is an uncommon entity that may mimic progressive and benign abdominal cystic tumours. Despite the frequency in use of prenatal ultrasonography, giant hydronephrosis may still be seen in adult population.

Contrast enhanced CT abdomen and pelvis is the gold standard diagnostic modality for diagnosing giant hydronephrosis and supported with Intravenous pyelogram.

Giant hydronephrotic kidney can cross the midline and pose as a diagnostic dilemma, therefore we emphasise that in an obscure case of ascites, the possibility of hydronephrosis has to be considered before paracentesis is attempted.

In a non functioning giant hydronephrotic kidney, nephrectomy is the surgical option of choice.

5.References

- [1] Yang W, shen S, Wa C. Hydronephrosis and giant hydronephrosis. Chinese Med]. 1958; 77: 257-259.
- [2] Tombari AA, Power RF, Harper JM, Politano VA. Giant hydronephrosis:a case report with reiew of literature. J Urol. 1968;100(2):100-120.
- [3] Hricak, H., Cruze, R.and Romonaski, R. Renal parenchymal disease: sonographic-histological correlation. Radiology. 1982, 144:141-148.
- [4] Hinman,F.and Helper,A.B. Experimental hydronephrosis:the effect of ligature of one branch of renal artery on its rate of development.iv. simultaneous ligation of the posterior branch of renal artery,and the ureter on the same side. Arch Surg. 1926,12:830-836.
- [5] WeilE, Rosenberg B.Massive hydronephrosis simulating ascites. Arch. Int. Med.1962;110:237.
- [6] Papin Edmund. Les Hydronephrosis.paris Doin (Quoted by sterling).
- [7] Crocks KK,Hendren WH, Pfister RC.Giant hydronephrosis in children. J Pediatr Surg. 1979; 14:844.
- [8] Glass S. Cited by P] Dennehy. Giant hydronephrosis in a double kidney. Br j urol. 1953;25:247-251.

- [9] Yang WT, Metrewell C. Giant hydronephrosis in adults. A great mimic. Early diagnosis with ultrasound. Postgrad Med J. 1995;71:409.
- [10] Kaushik, S.R, and Sachdev, H.S. Giant hydronephrosis: a case report. Ind j Surg. 1973,35:240.
- [11] M.S Ansari, Iqbal Singh and A.K. Hemal Giant hydronephrotic kidney mimicking intestinal obstruction. Int j urology and nephrology. 2003; 35: 319-320.

© Copyright 2010 BioMedSciDirect Publications IJBMR -ISSN: 0976:6685.
All rights reserved.