Int J Biol Med Res. 2012; 3(2): 1680-1689

BioMedSciDirect Publications

Contents lists available at BioMedSciDirect Publications

International Journal of Biological & Medical Research

Journal homepage: www.biomedscidirect.com

Original Article

A comparative evaluation of combination of anorganic bone matrix (abm) / cell binding peptide (p- 15) and collagen membrane (gtr), with collagen membrane alone in human periodontal infrabony defects - a clinical and radiographic study

Priyanka G. Jaiswal[a], Ishan R. Tiwari[a], Ramesh S.Chavan[a], Tony Kurien J[a], Manohar L. Bhongade[a], Pankaj Banode[b], Quazi Syed Zahiruddin[c*]

[a] *Senior Lecturer, Reader, Professor and Head, Department of Periodontics and Implant dentistry, Sharad Pawar Dental College and Hospital, Sawangi (Meghe), Wardha, Maharashtra State, India 442004*

[b] *Associate Professor, Dept. of Radiology, Jawaharlal Nehru Medical College, Datta Meghe Institute of Medical Sciences, Sawangi (Meghe), Wardha, Maharashtra State, India 442004*

[c*] *Associate Professor, Department of Preventive and Medicine, Jawaharlal Nehru Medical College, Datta Meghe Institute of Medical Sciences Sawangi (Meghe), Wardha, Maharashtra State, India 442004*

ARTICLE INFO

Keywords:
Anorganic bone matrix
Cell binding peptide
Bioabsorbable collagen (type I and III) membrane,
Infrabony defects.

ABSTRACT

ABM/P-15 demonstrated true periodontal regeneration. Study aims to compare clinical and radiographic outcomes of ABM/P-15 and collagen membrane with collagen membrane alone in the treatment of infrabony defects after 6 months period. Method and Materials: Experimental study in 20 interproximal defects in 13 patients. 6 weeks after completion of basic therapy, probing pocket depth, clinical attachment level, Gingival Recession and Radiographic defect depth were recorded as baseline values. The defects were surgically accessed and debrided. The defect site in a test group were grafted with ABM/P-15+collagen membrane, in control group were grafted with collagen membrane. 6 months post-surgery, clinical and radiographic assessments for soft tissue and hard tissue were performed. Results: ABM/P-15+GTR group demonstrated significantly better mean PPD reduction of 4.74 ± 0.67 mm, CAL gain of 4.70 ± 0.79 mm, and defect fill of 4.10 ± 1.28 mm (83.33%) as compared to 3.34 ± 0.61 mm, 3.12 ± 0.75 mm, 2.90 ± 0.69 mm (62.83%) respectively in the GTR alone group. Conclusion: ABM/P-15 can be used with GTR in the treatment of infrabony defect as it resulted in a significant added benefit in terms of CAL gains, PPD reductions and radiographic defect fill compared to GTR alone. Scientific Rationale for Study: The ultimate goal of periodontal therapy is to regenerate the components of periodontium that was affected by periodontitis. Current research is directed towards improvement of techniques and materials with regards to bone graft, GTR and combination therapy to achieve predictable periodontal regeneration in human infrabony periodontal defects. Principal Findings: 6 months post-surgical examination revealed that regenerative approach using ABM/P-15 in combination with collagen membrane (GTR) in human infrabony defects resulted in a significant added benefit in terms of CAL gains, PPD reductions and radiographic defect fill compared to collagen membrane alone.Practical implications: ABM/P-15 in combination with GTR improves the success rate of GTR.

© Copyright 2010 BioMedSciDirect Publications IJBMR -ISSN: 0976:6685. All rights reserved.

1. Introduction

The regeneration of periodontal attachment after the natural attachment has been destroyed is a continuing challenge in periodontal therapy. The ultimate goal of periodontal therapy is to regenerate the periodontium that was affected by periodontitis.

* Corresponding Author : Quazi Syed Zahiruddin
Associate Professor
Department of Preventive and Medicine,
Jawaharlal Nehru Medical College,
Datta Meghe Institute of Medical Sciences
Sawangi (Meghe), Wardha, Maharashtra State, India 442004
E.mail: zahirquazi@rediffmail.com

©Copyright 2010 BioMedSciDirect Publications. All rights reserved.

Clinical and histological studies [1,2] have indicated that guided tissue regeneration procedure using the technique of selective repopulation of the defect with periodontal ligament cells can promote new attachment and bone fill of infrabony defects. However, the success of guided tissue regeneration was depend on the size and nature of the defects. Larger areas of osseous defect (> 4 mm high) tend to present lower success rate with guided tissue regeneration [3]. Several biomaterials like Enamel matrix proteins [4], Growth factor [5] , and bone morphogenetic proteins [6] have been used to improve the success rate of guided tissue regeneration. Recently, the use of ABM/P-15 for the treatment of human infrabony defects has demonstrated true periodontal regeneration in both clinical [7,8] as well as histological studies[9, 10].

The peptide P-15 is a synthetic clone of the 15-amino acid sequence Type-I collagen, plays an important role in the binding of cells, particularly fibroblasts and osteoblasts [7],and the initiation of other cellular events like migration, proliferation, and differentiation that are necessary for periodontal regeneration [11,12]. Based on this concept, the ABM/P-15 combination was developed. ABM/P-15 consists of an anorganic bovine-derived bone matrix (ABM) coated with a synthetic cell-binding peptide (P-15).

Therefore, the present randomized parallel design, controlled clinical and radiographic study was undertaken to compare the effectiveness of combination of ABM/P-15, a cell binding peptide and guided tissue regeneration by using a collagen membrane barrier with that of collagen membrane alone in the treatment of human infrabony defects, using the clinical change in clinical attachment level, probing pocket depth, and radiographic bone fill over the six month period as measures of outcome.

2. Methods and Materials

A total of 13 patients (12 females, 1 male), age range 19-40 years (mean age – 26 ± 7.38 years) from the outpatient department of Periodontics, Sharad Pawar Dental College, Sawangi (Meghe), Wardha were enrolled in the study using the following criteria:

2.1.Inclusion criteria:

1. Systemically healthy subjects.
2. Presence of at least 1 or 2 radiographically detectable interproximal osseous defects with a probing depth ≥ 5 mm and clinical attachment loss ≥5 mm following initial therapy.
3. Depth of the intraosseous component of the defect estimated as ≥3 mm by clinical and radiographic means.
4. Presence of at least ≥ 2 mm band of keratinized tissue around the test teeth.

2.2.Exclusion criteria:

1. Patients with unacceptable oral hygiene (Plaque score >1).
2. Smokers or who used any tobacco products.
3. Teeth with inadequate endodontic/restorative treatments, or defects extending into furcations and third molars
4. Teeth with mobility exceeding Grade II.
5. Patients previously treated by periodontal surgical therapy.
6. Pregnant females or lactating mothers.

After proper examination and diagnosis, initial therapy consisting of oral hygiene instructions, supragingival and subgingival scaling and root planing under local anesthesia and occlusal adjustment if necessary were performed. Plaque control instructions were repeated by examining patients once in 2 weeks. A complete re-evaluation examination was performed after patient achieved plaque score of ≤ 1 following completion of initial therapy, to determine patient's response to the therapy and to confirm the need for periodontal surgery.

Prior to initiating this study, the purpose and design of this clinical trial was explained to the patients and informed consent form was signed by every patient. The study protocol was first approved by the ethical committee of Datta Meghe Institute of Medical Sciences, Sawangi (Meghe), Wardha.

2.3.Study design and Randomization

A total of 20 interproximal defects in 13 patients were found suitable after initial therapy. Prior to surgery, selected defects were randomly assigned by a coin flip method to the test group and control group each consisting of 10 defects, according to randomized parallel design. The control group was treated by an open flap debridement and a bioabsorbable collagen membrane of porcine origin (BIO-GIDE, Geistlich Biomaterials, Geistlich Pharma AG, Switzerland), while the test group was treated by a combination therapy of a bioabsorbable collagen and ABM/P-15 (PepGen – P-15 ,DentsPly, FriaDent ,Ceramed , USA).

2.4.Clinical Measurements

The clinical measurements were recorded prior to surgery, 3 months and 6 months post surgery for the assessment of the results. Recording of clinical data was carried out by the operator and a cross examiner in all the patients. The cross-examiner was a post graduate student from the department of Periodontics. The evaluators were blinded as much as possible for the treatment provided to each defect. Mean value of the recording by two examiners were calculated for the presentation of the results.

Patient's oral hygiene status was evaluated by the Plaque index [13] as an expression of the level of full mouth supragingival plaque accumulation. Gingival inflammation was assessed by Papillary bleeding index [14]. The probing measurements recorded were probing pocket depth (PPD), clinical attachment level (CAL), and gingival recession (REC). All the measurements were recorded at six sites per tooth; for later calculations only the sites representing the deepest point of the defect was used. The probing measurements were measured with a computerized constant pressure probe i.e Florida probe, (Florida probe corporation, Gaineswille, FL, USA) with a constant probing force of 15 gm (pressure -154 N/cm2), tip diameter of 0.45 mm, precision of 0.2 mm and a probe length of 11 mm (Fig. 1). The cemento-enamel junction (CEJ) was used as the fixed reference point. In case where the CEJ was not clearly visible, the lower border of the groove on acrylic stent, which covers the experimental tooth was used as reference point to measure attachment level.

Fig. 1. Preoperative view showing Florida probe in position

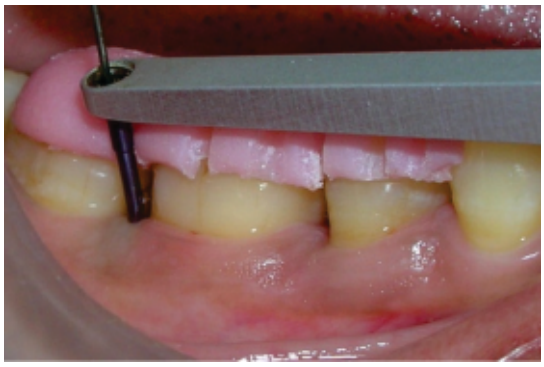

An intra-oral periapical radiograph (IOPA) was taken of each selected site with long cone (XCP Rinn, Dentsply) paralleling technique at baseline and after 6 months of surgery to measure the radiographic defect depth (DD) and to calculate the percentage of bone fill. Radiographic measurement was obtained utilizing a film mount with millimeter grid scale (Nix Company Ltd. Tokyo, Japan). These are pocket mount type grids for intraoral films. Grid scale lines are printed at 1 mm intervals with bold lines at 5 mm intervals. The developed IOPA film was inserted in the mount to measure defect depth. Vertical linear distances between the most coronal interproximal extension of bone crest and the apical most part of the defect were obtained by mounting the grids (Fig.2).

Fig.2. Pre-operative IOPA showing vertical defect on mesial surface of tooth # 30

2.5.Surgical procedure

Immediately before the surgical treatment, the patient was made to rinse the mouth with 0.2% chlorhexidine Gluconate (Hexidine, ICPA lab, India.) solution for 1 minute. The patient was draped to expose only the oral cavity. Asepsis was maintained throughout the procedure. The area subjected to surgery was anaesthetized either by nerve block or infiltration anaesthesia, depending on the surgical site, using local anaesthetic solution 2% xylocaine containing 1:1,00,000 epinephrine (Ligno-Ad local anaesthetic, Proxim Remedies, Vishal Dentocare Pvt. Ltd., India).

Conventional approach consisting of a periodontal access flap was initiated by intracrevicular (sulcular) incisions using Bard-Parker number 12 and 15 surgical blades on the buccal and lingual aspects. The incisions were carried as far interproximally as possible to preserve the entire interdental papillae so as to achieve primary wound closure. A tooth each mesial and distal to the defect-associated tooth was included in the flap. If necessary, divergent vertical relieving incisions were made one tooth away from the defect, where further access was required.

Full-thickness (mucoperiosteal) flaps were reflected using a periosteal elevator (24G Hu-Friedy, USA) to expose alveolar bone in the area of osseous defect. Extreme care was taken to avoid flap perforation or loss of papillae during removal of granulomatous tissue from the lesion adhering to inner aspect of the flap.

The osseous defect was debrided off granulation tissue using hand instruments (Gracey curettes, Hu-Friedy, USA), ultrasonic instruments (EMS, miniPiezon], thus exposing the root surface, alveolar bone and periodontal ligament. Any granulomatous tissue or epithelium adherent to the inner surface of the flap or papillae was judiciously removed taking care so as to not over thin the flap. The root surfaces were planed to remove plaque, calculus by ultrasonic and hand instrumentation. The root surfaces were planed until a smooth hard consistency was obtained.

At this stage, the depth of the interproximal osseous defect was measured and classified depending on the number of bony walls present (Fig.3). Intramarrow penetration was performed with a half round bur, in case insufficient bleeding from the walls of the lesion.

Fig.3. Configuration and Defect depth of intrabony defect

A sterile template i.e, sterile aluminium foil was utilized to obtain the approximate dimension & shape of the membrane (Fig.4). The membrane was trimmed in such a way that it overlaps the alveolar bony walls of the defect by at least two millimeters to allow complete bone contact and to prevent gingival connective tissue invasion below the material. The membrane was trimmed so that it was 1.5 mm to 2 mm wider than the interproximal space. This

was an attempt to achieve optimum adaptation to the root surface and underlying bone by creating a larger area of contact. Prior to the membrane placement, sutures were placed in the flap without tying the knot to allow rapid flap closure after membrane placement. No sutures were needed for stabilization of the membrane, as after hydration (with blood), it was well adapted and adhered naturally to the bone and root surfaces (Fig.5).

Fig. 4. Template design and Trimmed Bioresorbable membrane



Fig. 5. Membrane placed over the defect

In test sites before suturing, the membranes were lightly raised on one side to fill the defect with ABM/P-15 material (PepGenP-15 putty peptide enhanced regenerative bone graft). According to manufacturer's directions, using a sterile spatula the ABM/P-15 peptide enhanced bone graft material in particulate form was mixed thoroughly with an inert, biocompatible carrier gel, composed of highly purified, high molecular weight viscoelastic sodium hyaluronate in phosphate buffered saline, in sterile mixing container, until the mixture was homogenous in putty consistency (Fig.6). The sodium hyaluronate carrier forms the matrix, which improves the handling characteristics and helps to contain the graft particles at the defect site. ABM/P-15 material was placed and packed into the defect up to adjacent alveolar crest walls to fill, but not to overfill the defect (Fig.7).

Fig. 6. ABM/P15 (Putty consistency)

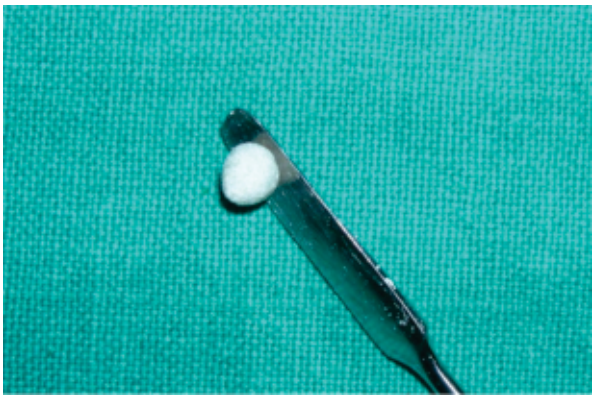

Fig. 7. ABM/P-15 and GTR membrane in place

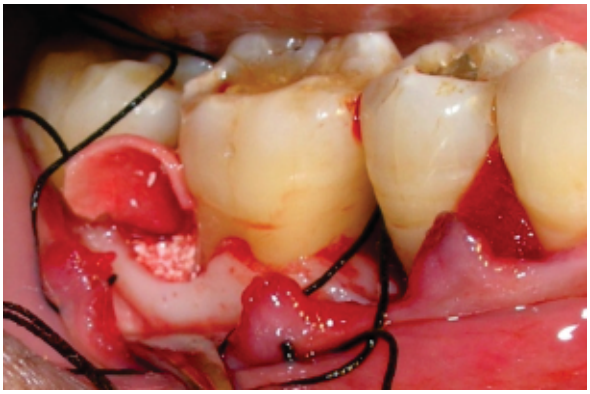

The mucoperiosteal flap was replaced to slightly coronal to cemento-enamel junction and sutured by using nonabsorbable black braided silk suture (Mersilk, Ethicon, Johnson Ltd) (Fig.8) using internal vertical mattress technique. Primary tension free wound closure was achieved to avoid post operative material contamination. The surgical site was dressed with periodontal dressing (Coe-Pak, TM, GC, Inc, ALSIP, IL, USA), on the buccal and lingual aspects (Fig.9).

The surgical procedure for the control group was identical to the procedure of the test group except the omission of the placement of ABM/P-15 material into the osseous defect.

Fig. 8. Suturing of flaps

Fig. 9. Periodontal pack placed

2.6.Post-Operative Care

Antibiotic coverage consisting of amoxicillin 500mg three times a day and analgesics consisting of a combination of Ibuprofen 325 mg and Paracetamol 400mg was prescribed for the 5 days during post surgical period. Patients were instructed to rinse twice daily with 0.2% Chlorhexidine Gluconate (Hexidine, ICPA health products ltd, India.) for six weeks. Periodontal dressing and sutures were removed 8-10 days post surgery. No mechanical oral hygiene procedures or chewing in the treated area was allowed for six weeks. After six weeks, patients were instructed to resume mechanical oral hygiene measures, including careful brushing with an ultra soft toothbrush (Plakoff Plus, ICPA health products ltd, India.), and interdental cleaning with an interdental brush (Plakoff Proxa tooth brush, ICPA health products ltd, India) and to discontinue chlorhexidine.

2.7.Maintenance Care (Months 1, 3 and 6)

The patients were recalled at 1, 3 and 6 months post surgery. All the patients received oral hygiene instructions and full mouth professional prophylaxis in the form of supragingival scaling by ultrasonic instruments at each follow up visit. Neither probing nor subgingival instrumentation was performed during the first six months post surgical period.

2.8.Statistical Analysis [15]

The means and standard deviations for PPD, CAL, REC and defect depth at baseline and at 6 months post-surgery were calculated for both groups. The Student's paired t-test was used to compare the data from the baseline to those at 6 months for each treatment group. Comparisons between treatment groups at baseline and 6 months post-surgery were accomplished with the Student's unpaired t-test. If the probability value (p) was more than 0.05, the difference observed was considered non-significant and if less than 0.05, it was considered significant.

3. Results

Wound healing was uneventful. There was no untoward effects, allergy, infection or patient complaints related to graft material. ABM/P-15 appeared to be clinically well tolerated by the periodontal tissues and also particle exfoliation was not noted. No membrane had to be removed, nor any site eliminated from the study. None of the selected patients dropped out before the termination of the study. In general, all the patients showed good oral hygiene throughout the study period. The mean PI score and PBI score during 6 month period remained significantly low compared to baseline measurement indicating satisfactory improvement in oral hygiene and gingival condition throughout the study period. At baseline, no statistically significant differences in any of the investigated parameters were observed between the test and control groups ($p>0.05$), indicating that the randomization process was effective.

3.1. Clinical outcomes at 6 months

3.1.1.Probing Pocket Depth (PPD)

At 6 months, the mean PPD reduction was 4.74 ± 0.67 mm for the test group and 3.34 ± 0.61 mm for the control group. Student's paired t-test indicated that both the test (ABM/P-15 + GTR) and control (GTR) groups showed significantly greater mean PPD reduction at 6 months compared to baseline ($p<0.05$). When the differences in mean PPD reductions for the test group (4.74 mm) versus control group (3.34 mm) at 6 months were analyzed by Student's unpaired t-test, significantly ($p<0.05$) a greater reduction in mean PPD was observed in test (ABM/P-15 + GTR) group compared to the control (GTR) group, with added benefit of 1.40 mm PPD reduction in test group. The mean residual probing pocket depth at 6 months was 2.65 ± 0.31 mm for the test group and 4.00 ± 0.50 mm in the control group.

Frequency Distribution: 100% of sites treated with ABM/P-15 + GTR showed pocket depth reduction of more than 2.5 mm. Conversely, only 90% of GTR sites showed PPD reduction of more than 2.5 mm and 10% sites showed PPD reduction of less than 2.5 mm.

3.2.Clinical Attachment Level (CAL)

In the test group, the mean CAL gains of 4.70 ± 0.79 mm was observed , while the control (GTR) group displayed mean CAL gains of 3.12 ± 0.75 mm. The observed differences between baseline CAL and 6 months CAL were analyzed by Student's paired t-test, and were found to be statistically significant in both the groups ($p<0.05$). When the differences in CAL gains for the test group (4.70 mm) versus control group (3.12 mm) were analyzed by Student's unpaired t-test, significantly higher mean CAL gain was observed in the test group compared to the control group. The magnitude of the observed additional benefit was 1.58 mm in the test group.

Frequency Distribution: The ABM/P-15 + GTR treatment resulted 100% of sites gaining 2.5 mm or more CAL, whereas only 70% of the sites with GTR treatment resulted gain in CAL more than 2.5 mm.

3.3.Gingival Recession (REC)

At 6 months, the mean increase in gingival recession was 0.04 ± 0.47 mm in the test group and 0.22 ± 0.39 mm in the control group. Increase in gingival recession was not found to be statistically significant in both the groups when compared to baseline. Also no statistically significant difference was found in increase in gingival recession between the test and control groups ($p>0.05$). Both the treatment groups i.e. ABM/P-15 + GTR and GTR alone resulted in increase in REC of 1 mm or more at 10% of sites.

3.4.Radiographic Analysis of Defect Depth (DD):

At 6 months, the mean reduction in radiographic Defect Depth of 4.10 ± 1.28 mm (83.33%) was observed in the test (ABM/P-15 + GTR) group, while the control (GTR) group displayed mean reduction of radiographic defect depth of 2.90 ± 0.69 mm (62.83%). Statistically significant reductions of radiographic defect depth were recorded for the both test group as well as the control group ($p<0.05$). When comparison was made between the test and control groups using the Student's unpaired t-test, significantly greater reduction of radiographic defect depth was observed in test group ($p<0.05$), with additional benefit of 1.2 mm (20.50 %) in ABM/P-15 + GTR group.

Table 1. Distribution and configuration of treated intrabony defects and tooth location

Intrabony Defects	Test Group (n=10)	Control Group (n=10)
3-wall	1	4
2½- wall	3	3
2 wall1	1	3
½ wall	4	-
1 wall	1	-
Tooth Location	Test Group (n=10)	Control Group (n =10)
Mandibular		
Premolars	1	2
Molars	4	3
Maxillary		
Premolars	1	-
Molars	4	5

Table 2. Plaque Index (PI) and Papillary bleeding Index (PBI) scores at Baseline, 3 months and 6 months after surgery. (Mean SD)

Parameters	Baseline	3 months	Difference	6 months	Difference
PI	0.78 ±0.036	0.65±0.033	0.65±0.033	0.71± 0.025	0.07±0.031S
PBI	0.78 ±0.05	0.62±0.026	0.62±0.026	0.67± 0.023	0.11±0.04S

S : Significant ($p < 0.05$)

Table 3. Baseline Defect Characteristics for Test (ABM/P-15 + GTR) and Control (GTR) Groups (Mean ± SD; in mm)

Parameters (at site)	Test Group	Control Group	Difference	p value
Probing Pocket Depth (PPD)	7.39 ± 0.81	7.34 ± 0.77	0.05 ± 0.35	0.89NS
Clinical Attachment Level (CAL)	7.49 ± 0.87	7.36 ± 0.75	0.13 ± 0.36	0.72NS
Gingival Recession(GR)	0.10 ± 0.31	0.02 ± 0.06	0.08 ± 0.10	0.44NS
Radiographic Defect Depth(DD)	4.90 ± 0.99	4.80 ± 1.39	0.10 ± 0.54	0.85NS

S : Significant ($p < 0.05$)

Table 4. Clinical and Radiographic parameters at Baseline and at 6 months post surgery for Test (ABM/P-15 + GTR) Group (Mean ± SD; in mm)

Parameters (at site)	Baseline	6 months	Difference	p value
PPD	7.39 ± 0.81	2.65 ± 0.31	PPD Reduction 4.74 ± 0.67	0.000S
CAL	7.49 ± 0.87	2.79 ± 0.57	CAL Gain 4.70 ± 0.79	0.000 S
REC	0.10 ± 0.312	0.14 ± 0.37	REC Increase 0.04 ± 0.47	0.798NS
DD	4.90 ± 0.99	0.80 ± 0.91	Decrease in DD 4.10 ± 1.28	0.000 S

S : Significant ($p < 0.05$)
NS: Non Significant ($p > 0.05$)

Table 5. Clinical and Radiographic parameters at Baseline and at 6 months post surgery for Control (GTR) group (Mean ± SD; in mm)

Parameters	Baseline	3 months	Difference	Difference
PPD	7.34± 0.77	4.00±0.50	PPD Reduction 3.34±0.61	0.000 S
CAL	7.36 ±0.75	4.24±0.69	CAL Gain 3.12±0.75	0.000 S
RE	0.02± 0.06	0.24±0.41	REC Increase 0.22±0.39	0.111NS
CDD	4.80 ±1.39	1.90±1.02	Decrease in DD 2.90±0.69	0.000 S

S : Significant (p < 0.05)
NS: Non Significant (p > 0.05)

Table 6. Comparison of changes in Clinical and Radiographic parameters at 6 months between Test group (ABM/P-15 + GTR) and Control group (GTR) (Mean ± SD; in mm)

Parameters (at site)	Test Group (ABM/P15+GTR)	Control Group (GTR)	Difference	p-value
PPD	4.74 ±0.67	3.34±0.61	1.40±0.89	0.001S
CAL	4.70± 0.79	3.12± 0.75	1.58±1.16	0.002S
REC	0.04±0.47	0.22± 0.39	0.18±0.63	0.394NS
Defect mm	4.10 ±1.28	2.90±0.69	20.50± 19.65	-
Fill %	83.33± 18.39	62.83±15.47		

S : Significant (p < 0.05)
NS: Non Significant (p > 0.05)

Table 7. Frequency distribution of clinical characteristics after 6 months at Test (ABM/P-15 + GTR) and Control (GTR) sites

Parameters		Test Group (ABM/P-15 + GTR) No. of sites (%)	Control Group (GTR) No. of sites (%)
PPD Reduction (mm)	>2.5	10(100%)	9 (90%)
	<2.5	0 (00%)	1 (10%)
CAL Gain (mm)	>2.5	10 (100%)	7 (70%)
	<2.5	0 (00%)	3 (30%)
REC Increase (mm)	>1	1 (10%)	1 (10%)
	<1	9 (90%)	9 (90%)

Table 8. Mean baseline PPD and post-surgery residual PPD, CAL gains and increase in REC in Test (ABM/P-15 + GTR) and Control (GTR) groups (Mean ± SD; in mm)

Parameters	Test Group (ABM/P-15 + GTR)			Control Group (GTR)		
	PPD	CAL	REC	PPD	CAL	REC
At Baseline	7.39±0.81	7.49 ±0.87	0.10±0.31	7.34±0.77	7.36±0.75	0.02±0.06
At 6 months	Residual PPD 2.65 ±0.31	2.79±0.57	0.14± 0.37	Residual PPD 4.00 ±0.50	4.24±0.69	0.24±0.41
Difference	4.74 ±0.67	CAL Gain 4.70± 0.79	REC increase 0.04± 0.47	3.34 0.±61	CAL Gain 3.12±0.75	REC increase 0.22±0.39

4. Discussion

Change in the clinical attachment levels (CAL) following regenerative therapy is the single most commonly used clinical outcome variable in regenerative studies. In the present study, statistically significant gains of mean CAL were observed in both ABM/P-15 combined with GTR and GTR alone groups at 6 months (4.70 mm and 3.12 respectively). The gain in CAL observed in GTR alone group compares well with those reported in other clinical trials. Cortellini et al [16] in one year follow-up of thirty-six patients after the treatment of deep interproximal intrabony defect with bioresorbable membrane reported mean CAL gain of 4.6 mm. Parodi et al [17] reported mean CAL gain of 4 mm at 5 months follow-up after the treatment of circumferential osseous defects on maxillary molar by using DPPA cross-linked collagen membrane.

At 6 months post-surgery, a statistically significant greater amount of mean CAL gain (1.58 mm) was observed in the ABM/P-15 combined with GTR group when compared to the GTR alone group. Since, no clinical data are available in the literature on ABM/P-15 + GTR, the results obtained in present study were compared with other studies reported on GTR in combination with other regenerative biomaterials. Lekovic et al [4] reported mean CAL gain of 3.89 mm on buccal sites and 3.78 mm on lingual sites in a group treated with combination of bovine porous bone mineral with Enamel matrix proteins and a bioabsorbable membrane. Lekovic et al [5] evaluated the clinical effectiveness of combination of platelet-rich plasma (PRP) with bovine porous bone mineral (BPBM), and guided tissue regeneration (bioabsorbable membrane) for the treatment of intrabony defects in humans and observed mean CAL gain of 4.12 mm on buccal sites and 4.16 mm on lingual sites as compared to 3.78 mm on buccal sites and 3.84 mm on lingual sites in PRP + BPBM group at 6 months. The mean CAL gain observed in these studies are comparable to the mean CAL gain recorded in the present study. In the present study, significantly greater amount of mean CAL gain of 1.58 mm was observed in ABM/ P-15 combination with GTR treated group in comparison with GTR alone treated group. This added benefit of 1.58 mm gain of CAL in ABM/P-15 combined with GTR treated group could be related to molecular characteristic of ABM/P-15 that enhances cell attachment, and proliferation. ABM/P-15 enhances the attachment and proliferation of periodontal ligament fibroblasts and bone marrow mesenchymal stromal cells to the ABM [11,18], induces mineralizing matrix production by periodontal ligament fibroblast and induces an osteogenic phenotype in this cells[11].

From the clinical standpoint it was more significant to observe that 100% of the treated sites with combination of ABM/P-15 + GTR therapy experienced the CAL gain of 2.5mm or more, while only 70% of the sites treated with only GTR showed CAL gain of 2.5mm or more.

The presence of filling material underneath the membrane sustained the membrane in the coronal portion of the defect, where the architecture could not guarantee an adequate support to the bioabsorbable membrane alone[19]. Thus, results confirm the principle that the coronal limit to periodontal regeneration is set by the membrane position [19].

Reduction of pocket depth in order to limit the risk of local reinfection is a primary goal of periodontal therapy. Shallow pockets have a strong, negative predictive value for future disease progression, while deep pockets in treated areas are risk indicators for periodontal disease progression [20]. In the present study, pocket depth reduction was significant in both test and control groups. The mean PPD reduction obtained in sites treated with ABM/P-15 combined with GTR was 4.74 mm and 3.34 mm in GTR treated sites. A statistically significant greater reduction of PPD (1.40 mm) was observed in the ABM/P-15 combined with GTR group compared to the GTR alone group. The mean PPD reduction observed in the present study by using ABM/P-15 + GTR are comparable with other studies reported on GTR in combination with other regenerative biomaterials. Lekovic et al [4] reported mean PPD reduction of 4.95 mm on buccal sites and 4.74 mm on lingual sites treated with combination of bovine porous bone mineral with Enamel matrix proteins and a bioabsorbable membrane. Lekovic et al [5]reported mean PPD reduction of 4.19 mm on buccal sites and 4.21 mm on lingual sites in group treated with combination of platelet-rich plasma (PRP) with bovine porous bone mineral (BPBM), and guided tissue regeneration (GTR). Walters et al [2] compared Non-Porous (NP) or Porous (P) Teflon membrane in combination with ABM/P-15 and observed a mean PPD reduction of 4.7 mm and 4.3 mm respectively 9 months after surgery.

In the present study, the 100% of the sites treated with ABM/P-15 combined with GTR at 6 months showed the mean pocket depth reduction of > 2.5 mm, where as in control group (GTR), only 90% of the sites showed pocket depth reduction of > 2.5 mm and 10% of the sites showed pocket depth reduction of < 2.5 mm.

Periodontal surgeries are frequently associated with gingival recession, an adverse effect that concerns both patients and clinicians. Regenerative approaches, however, potentially could help to limit this unwanted side effect. In the present study, increase in gingival recession (REC) was observed to a limited extent, in both the test (0.04 ± 0.47 mm) and control (0.22 ± 0.39 mm) groups at the end of 6 months

During 6 months, the infrabony lesions in this study, responded well to ABM/P-15 combined with collagen membrane treatment with regards to reduction in radiographic defect depth. It is the experience of the investigators [7] that the most accurate means of determining osseous defect response (crestal changes as well as with in the defect) is by direct visualization at reentry surgery, but a major disadvantage of re-entry procedure is a need of second surgical procedure to visualize the osseous defect. To overcome this difficulty, radiographic monitoring of alveolar bone changes has been utilized with various degrees of success [21]. Radiographic bone measurement is a non-invasive, painless alternative to direct bone measurement. Therefore in the present study, radiographic monitoring of alveolar bone changes was carried out as end point variables.

In the present study, reduction in radiographic defect depth was obtained. Defect depth reduction was significant in both test and control group at 6 months. The mean defect depth reduction at 6 months in test group was 4.10 mm (with 83.33% defect fill) and 2.90 mm in control group (with 62.83% defect fill). The mean defect depth reduction was significantly greater i.e. 1.2 mm (20.50 %) in test group compared to control group. These findings are in accordance with previous reported studies. Lekovic et al [4] reported mean defect fill of 4.76 mm on buccal sites and 4.81 mm on lingual sites treated with combination of BPBM + EMP + GTR as compared to 1.78 mm on buccal sites and 1.67 mm on lingual sites in OFD group. Lekovic et al [5] in a reentry study reported defect fill of 4.96 mm on buccal sites and 4.78 mm on lingual sites in group treated with combination of PRP + BPBM + GTR. Berkman et al [22] reported a gain in defect fill of 3.4 to 3.5 mm in sites treated with β-TCP/GTR/PRP group as compared to 2.0 mm in β-TCP +PRP.

The most reliable outcome variable for assessing periodontal regeneration is human histology. Due to ethical considerations and patient management limitations, no histological evidence was obtained to establish proof of periodontal regeneration. Based on the histological evidence from human material [9,23,24] it may be assumed that the clinical improvements following ABM/P-15 treatment may represent, at least to some extent, a real periodontal regeneration characterized by the formation of new cementum, periodontal ligament and alveolar bone. The importance of wound stability for bone for and periodontal regeneration has been reported [25]. The addition of P-15 peptide to ABM has been reported to enhance initial fibroblast attachment to the particles through biomimetics [26,27,11], whether these findings resulted in greater wound stability and thus enhanced regeneration can only be hypothesized.

Six months period may be considered too short to evaluate the effect of periodontal therapy, especially in dealing with grafting techniques and biomaterials. Yukna et al [28] stated in their long term study, the majority of clinical changes were previously achieved at the time of re-entry at 6-7 months, with no real further change from re-entry to 3 years. Therefore, six months time period in the present study could be considered adequate.

From the analysis of the results, and within the limitations of the study, it was concluded that: 6 months after surgery both therapies resulted in statistically significant improvements in terms of CAL gains and PPD reduction. Treatment with ABM/P-15 in combination with GTR resulted in a significantly higher CAL gain and PPD reduction in comparison with GTR alone. Grafting with ABM/P-15 in combination with GTR resulted in significantly greater radiographic defect fill compared to GTR alone. Regenerative approach using ABM/P-15 in combination with GTR for the treatment of human infrabony defects resulted in a significant added benefit in terms of CAL gains, PPD reductions and radiographic defect fill compared to GTR alone.

5.References

[1] Armitage GC. Periodontal diseases: Diagnosis. Ann Periodontol. 1996; 1: 37-215.

[2] Barboza EP, de Souza RO, Caula AL, Neto LG, de Oliveira FC, Durate ME. Bone regeneration of localized chronic alveolar defects utilizing cell binding peptide associated with anorganic bovine-derived bone mineral: a clinical and histological study. J Periodontol.2002; 73: 1153-1159.

[3] Berkman ZY, Tuncer O, Subasioglu T, Kantarci.A. Combined use of platelet-rich plasma and bone grafting with or without guided tissue regeneration in the treatment of anterior interproximal defects. J Periodontol.2007; 78:801-809.

[4] Bhatnagar RS, Qian J, Wedrychowska, Smith N. Design of boimimetic habitats for tissue engineering with P-15, a synthetic peptide analog of collagen. Tissue Eng; 5: 53-65.

[5] Bhatnagar RS, Qian JJ, Gough CA. (1997) The role in cell binding of beta bend with the triple helical region in collagen 1 chain: structural and biological evidence for conformational tautomerism on fibre surface. J Molecular Structure Dynamics.1999; 14: 547-560.

[6] Bhatnagar RS, Qian JJ. (1996) Enhanced cell attachment to anorganic bone mineral in the presence of a synthetic peptide related to collagen. J Biomed Mater Res. 31: 5458-554.

[7] Bjorn H, Halling A, Thyberg H. Radiographic assessment of marginal bone loss. Cited in: Vouros I, Aristimou E, Konstantinidis A. Guided tissue regeneration in infrabony periodontal defects following treatment with bovine bone mineral graft. A clilnical and radiographic study. J Clin Periodontol .2004;31: 908-917.

[8] Brunnel G, Piantoni P, Elharar F, Benque E, Martin P, Zahedi S. Regeneration of rat calvarial defects using a bioabsorbable membrane technique: Influence of collagen cross-linking. J Periodontol.1996; 67:1342-1348.

[9] Cochran D, Wozney J. Biological mediators for periodontal regeneration. Periodontol.2000; 10: 40-58.

[10] Cortellini P, Pini Prato G, Tonetti MS. Periodontal regeneration of human infrabony defects with bioabsorbable membranes. A controlled clinical trial. J Periodontol.1996; 67: 217-223.

[11] Gottlow J, Nyman S, Karring T, Lindhe J. Karring T. and Wennstrom J. New attachment formation in human periodontium by guided tissue regeneration. Case reports. J Clin Periodontol.1986; 13: 604-616.

[12] Lallier TE, Yukna RA, Marie SS, Moses R. the putative collagen binding peptide hastens periodontal ligament cell attachment to bone replacement graft materials. J Periodontol.2001; 72: 990-997.

[13] Lekovic V, Camargo PM, Weinlaender M, Kenney EB, Vasilic N. Combination use of bovine porous bone mineral, enamel matrix proteins, and a bioabsorbable membrane in intrabony periodontal defects in humans. J Periodontol.2001; 72: 583-589.

[14] Lekovic V, Camargo PM, Weinlaender M, Vasilic N, Kenney EB. Comparison of platelet-rich plasma , bovine porous bone mineral, and guided tissue regeneration versus platelet-rich plasma , bovine porous bone mineral in the treatment of intrabony defects: A Reentry study. J Periodontol.2002; 73: 198-205.

[15] Mahajan BK. Methods in Biostatistics . Ed 5. New Delhi, Jaypee Brothers. 1991;128-153.

[16] Mulhemann. HR. Psychological and chemical mediators of gingival health. J Prevo Dent.1977; 4:6.

[17] Paolantonio M. Combined periodontal regenerative technique in intrabony defects by collagen membranes and anorganic bovine bone. A controlled clinical study. J Periodontol .2002;73: 158-166.

[18] Parodi R, Santarelli G, Carusi G. Application of slow-resorbing collagen membrane to periodontal and peri-implant guided tissue regeneration. Int J Periodontics Restorative Dent.1996; 16: 175-185.

[19] Pontoriero R, Lindhe J, Nyman S, Karring T, Rosenberg E, Sonavi F. Guided tissue regeneration in the treatment of furcation defects in mandibular molars. A clinical study of degree III involvements. J Clin Periodontol.1989; 16: 170-174.

[20] Turesky S, Gilmore ND, Glickman I. Reduced plaque formation by the chloromethyle analogue of vitamine C. J Periodontol.1970; 41:41.

[21] Vastardis S, Yukna RA, Mayer ET, Atkinson BL. Periodontal regeneration with peptide-enhanced anorganic bone matrix in particulate and putty form in dogs. J Periodontol.2005; 76: 1690-1696.

[22] Walters SP, Greenwell H, Hill M, Drisko C, Pickman K, Scheetz JP. Comparision of porous and non-porous Teflon membranes plus a xenograft in the treatment of vertical osseous defects: A clinical reentry study. J Periodontol.2003; 74: 1161-1168.

[23] Wiekesjo UM, Nilveus RE, Selvig KA. Significance of early healing events on periodontal repair. A review. J Periodontol.1992; 63: 158-165.

[24] Yang XB, Bhatnagar RS, Li S, Oreffo RO. (2004) Biomimetic collagen scaffolds for human cell growth and differentiation. Tissue Eng 10: 1148-1159.

[25] Yukna RA, Callan DP, Krauser JT. Multi-center clinical evaluation of combination anorganic bovine-derived hydroxyapatitie matrix (ABM)/cell binding peptide (P-15) as a bone replacement graft material in human periodontal osseous defects. 6-month results. J Periodontol.1998; 69: 655-663.

[26] Yukna RA, Krauser JT, Callan DP, Evans GH, Cruz R, Martin M. Multi-center clinical comparision of combination anorganic bovine-derived hydroxyapatitie matrix (ABM)/cell binding peptide (P-15) and ABM in human periodontal osseous defects. 6-month results. J Periodontol.2000; 71: 1671-1679.

[26] Yukna RA, Krauser JT, Callan DP, Evans GH, Cruz R, Martin M. Thirty-six months follow-up of 25 patients treated with combination anorganic bovine-derived hydroxyapatitie matrix (ABM)/cell binding peptide (P-15) bone replacement grafts in human intrabony defects. I. clinical findings. J Periodontol.2002;73: 123-128.

[27] Yukna RA, Salinas TJ, Carr RF. Periodontal regeneration following use of ABM/P-15: A case report. Int J Periodontics Restorative Dent.2002; 22: 146-155.

© Copyright 2010 BioMedSciDirect Publications IJBMR -ISSN: 0976:6685.
All rights reserved.