



Contents lists available at BioMedSciDirect Publications

## International Journal of Biological & Medical Research

Journal homepage: [www.biomedscidirect.com](http://www.biomedscidirect.com)



### Case report

## “Atraumatic Management of Anterior Urethral Stone by Tube on Bougie Retrieval to Bladder”.

<sup>a</sup>Dr Rekha Patidar, <sup>b</sup>Dr B.C. Mewara, <sup>c</sup>Dr Naresh Damesha

Assistant professor Surgery, Jhalawar Hospital & Medical college society, Jhalawar, Rajasthan, India.

Medical Officer in Surgery Department Jhalawar Hospital & Medical College society, Jhalawar, Rajasthan, India.

Senior resident Surgery Jhalawar Hospital & Medical College society, Jhalawar, Rajasthan, India.

#### ARTICLE INFO

##### Keywords:

Cystolithotomy

Impacted anterior urethral stone

Less complications

Retrograde tube bouginage technique.

#### ABSTRACT

Simple bouginage technique in management of posterior urethral stone is well known but the same is failure in anterior urethral stone for dislodgement back into the bladder successfully till we came across and adopted modified tube on bouginage technique described by Dasgupta [1] ,for anterior urethral stone management too.

©Copyright 2010 BioMedSciDirect Publications IJBMR -ISSN: 0976:6685. All rights reserved.

### 1.Case report

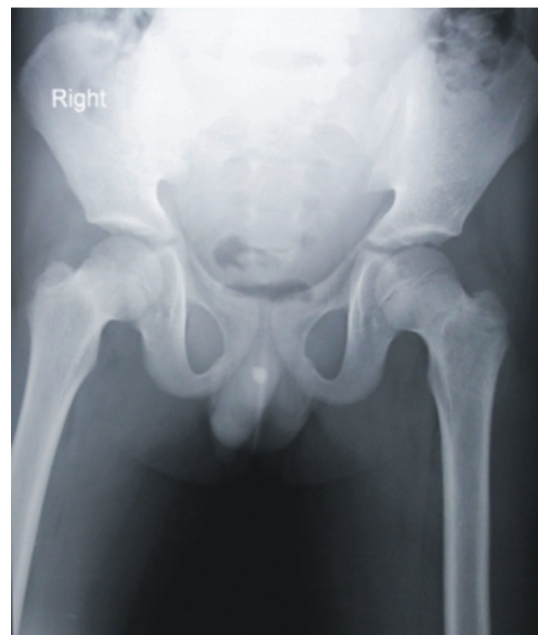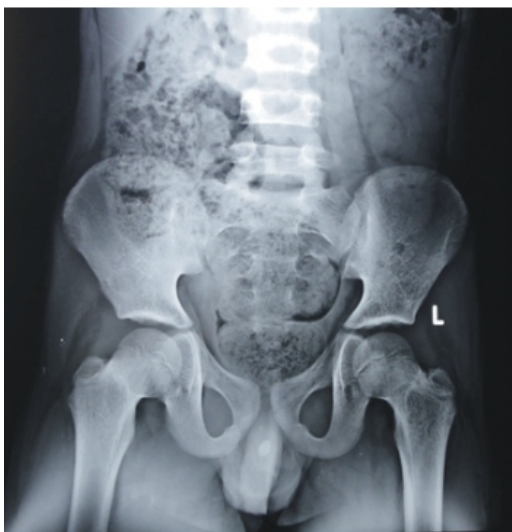Eight years old male child was admitted in our Hospital with acutely impacted anterior urethral stone with retention of urine (Fig. 1). The stone was dislodged back into the bladder by transurethral bouginage technique [1], and cystolithotomy immediately thereafter under general anesthesia.

#### Figure legends

Figure1. Radiograph shows the impacted calculus in anterior urethra.

In short, the appropriate size curved urethral bougie fitted snugly with plastic tube with its proximal bevelled end projecting over the end of bougie about half inch and the same introduced into the urethra which help in dislodgement of stone back in to the bladder (Fig.2).

Figure1. Radiograph shows the impacted calculus in anterior urethra.

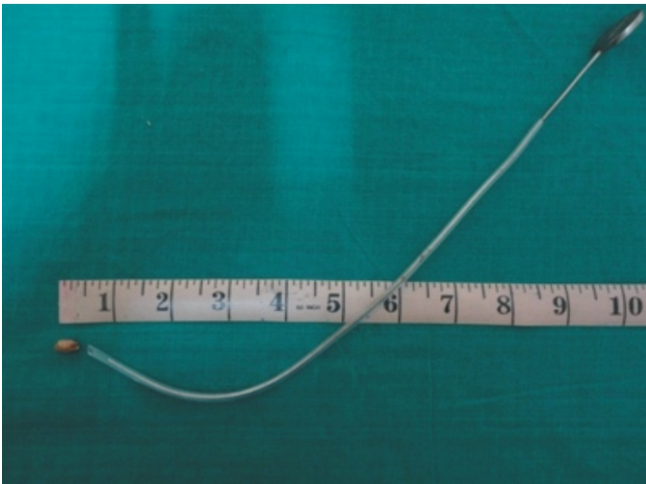


\* Corresponding Author : Dr Rekha patidar  
Quarter no. III/7, SRG Hospital and  
Medical College Campus, Jhalawar  
Rajasthan, India  
PIN Code- 326001  
Email- drrekhap@yahoo.com  
Mobile no.- +919414308276

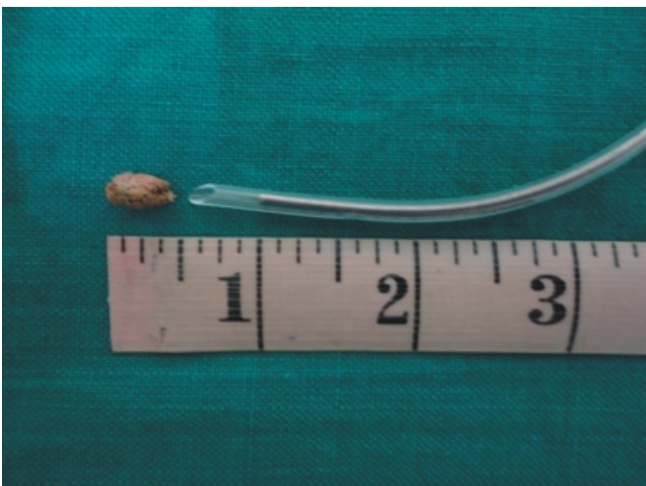## 2. Discussion

The anterior urethral stone can also be managed by urethrolithotomy but with associated consequent risk of urethral fistula or stricture. The anterior urethral stone can also be managed with endoscopic technique by various types of lithotripsy but this facility does not exist everywhere specially so in developing countries. Therefore dislodgement of the stone from anterior urethra retrogrades into the bladder and thereafter can be managed by endoscopic lithotripsy, extraction or lithotripsy and or by suprapubic cystolithotomy as in this case.

**Figure2. Shows tube slid on the bougie with beveled end projecting and extracted stone**



**Figure2. Shows tube slid on the bougie with beveled end projecting and extracted stone**



## 3. References

- [1] Dasgupta HK, Gupta VV. Tube- bouginage technic in the management of urethral stone (case reports). J postgrad Med. 1981; 27(3): 187-188.