



Contents lists available at BioMedSciDirect Publications

## International Journal of Biological & Medical Research

Journal homepage: [www.biomedscidirect.com](http://www.biomedscidirect.com)



### Original Article

# A study on the internal diameter of femoral artery and level of origin of profunda femoris artery

Shiny Vinila B H, Sridevi N S, Kumaraswamy R

Department of Anatomy, Sri Devaraj Urs Medical College, Kolar, Karnataka.

#### ARTICLE INFO

##### Keywords:

Femoral artery internal diameter  
profunda femoris artery  
Peripheral vascular diseases

#### ABSTRACT

Knowledge of internal diameter of femoral artery and variations in the level of origin of profunda femoris artery is important to surgeons and interventional radiologists as this artery is used in certain clinical procedures like cardiac catheterization, transarterial chemo embolization in the treatment of malignancy, arteriography in peripheral vascular diseases. The expanding scope of interventional radiology has prompted this study. The study was done by dissection method. The average internal diameter of femoral artery was observed as  $7.02 \pm 0.85$  mm. The knowledge of the site of origin of profundafemoris artery helps in avoiding iatrogenic femoral arteriovenous fistula or severe secondary haemorrhage, while performing femoral arterial puncture. The mean distance of origin of profundafemoris artery was observed as 4.13 cm and standard deviation was observed as 0.80 cm; so the average distance ranges  $4.3 \pm 0.80$  cm these measurements are useful as this artery is used for arteriography, Doppler imaging and magnetic resonance imaging. Clinicians should be aware of vascular anatomy and its variations.

© Copyright 2010 BioMedSciDirect Publications IJBMR -ISSN: 0976:6685. All rights reserved.

### 1. Introduction

The proper knowledge of the course and ramification of the blood vessels of the lower limb is very important for surgeons and interventional radiologists. The femoral artery is a continuation of the external iliac artery. It begins behind the inguinal ligament, midway between the anterior superior iliac spine and the pubic symphysis, descends along the anteromedial part of the thigh in the femoral triangle, enters and passes through the adductor canal, and becomes the popliteal artery. the profunda femoris artery is a large branch that arises laterally from the femoral artery 3.5 cm distal to the inguinal ligament (from midpoint of inguinal ligament).[1] Accurate knowledge of anatomical variations regarding origins of the profunda femoris is important for clinicians in the present modern era of interventional radiology. The profunda femoris artery is frequently incorporated in vascular reconstructive procedures in the proximal leg.[2] The knowledge of variations in height origin of profunda femoris

artery and its branches distribution is of great significance for preventing flap necrosis, particularly tensor fascia lata, when used in plastic and reconstructive surgery.[3]

### 2. Materials and Methods :

The material for the present study comprises of 40 lower limbs of adult human cadavers irrespective of their sex. The study was done by dissection method. The internal diameter of femoral arteries was measured with radial calipers, readings were taken in millimeters and the distance of origin of *profunda femoris* artery was measured from midpoint of inguinal ligament by using centimeter scale and the observations were noted.

### 3. Observations and Results :

The observations, findings and analyzed data of the undertaken study have been represented in the following tables.

\* Corresponding Author : **B H Shiny Vinila**

Tutor , Department of Anatomy,  
Sri Devaraj Urs Medical College,  
Tumakuru, Kolar  
Ph : 9916758571  
Email: [bhvineela@yahoo.com](mailto:bhvineela@yahoo.com)

©Copyright 2010 BioMedSciDirect Publications. All rights reserved.

#### 4. Results:

**Table 1: Internal Diameter of Femoral Artery In Adult Cadavers. (n=40)**

Range in millimeters	No. of cases	
	Right side	Left side
4.0-5.0	1	1
5.1-6.0	2	2
6.1-7.0	2	3
7.1-8.0	15	14

The internal diameter of the femoral artery on the right and left side were also recorded.

The mean diameter = 7.02 and standard deviation (SD) = 0.85; so the average internal diameter is  $7.02 \pm 0.85$  mm.

On both sides it was 4.0 to 5.0 mm in 5 % cases and 5.1 – 6.0 mm in 10% cases.

##### On the left side

Mean = 6.95 and SD = 0.90; so the average internal diameter is  $6.95 \pm 0.90$  mm.

It was observed to be 6.1 to 7.0 millimeters in 2 or 10 % cases.

It was observed to be 7.1 to 8.0 millimeters in 15 or 75 % cases.

##### On the right side

Mean = 7.09 and SD = 0.84; so the average internal diameter is  $7.09 \pm 0.84$  mm.

It was observed to be 6.1 to 7.0 millimeters in 3 or 15 % cases

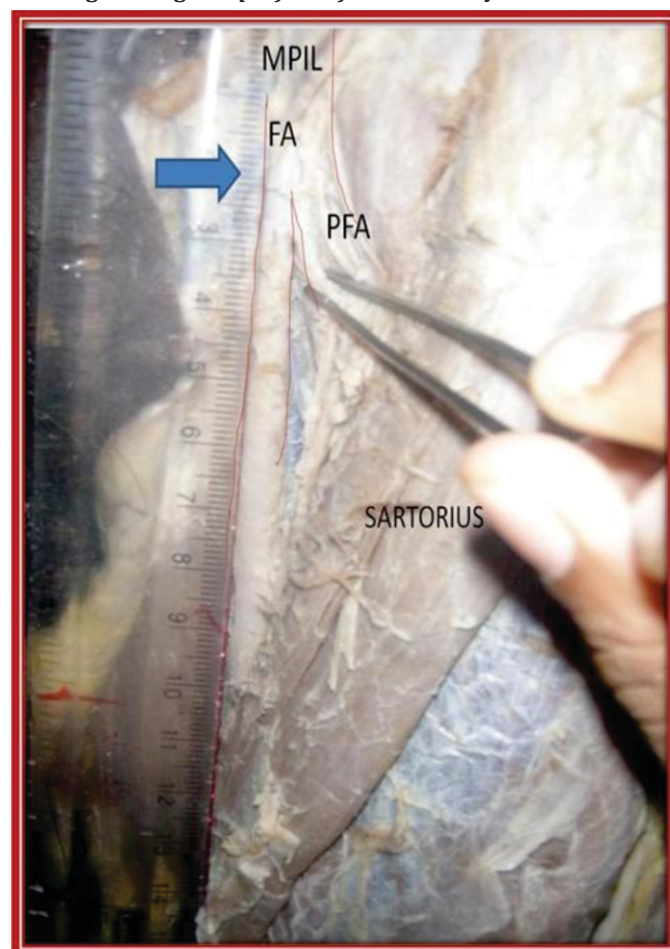
It was observed to be 7.1 to 8.0 millimeters in 14 or 70 % cases.

**Table 2: Distance Of Origin Of Profunda Femoris From The Midpoint Of Inguinal Ligament (n= 40)**

Range in millimeters	No. of cases	
	Right side	Left side
20 – 30	0	4
31 – 40	8	8
41 – 50	10	0
51 – 60	2	0

The distance of origin of *profundafemoris* artery from femoral artery was measured with scale in millimeters from midpoint of inguinal ligament. The mean = 4.13 and SD = 0.80; so the average distance ranges  $4.3 \pm 0.80$  cm.

**Photo 1: Higher origin of *profundafemoris* artery**



MPIL – Midpoint of inguinal ligament

FA – Femoral artery

PFA – Profundafemoris artery

##### On left side

Mean = 3.87 and SD= 0.88; so the average distance is  $3.87 \pm 0.88$  cm.

In 40 % cases it was observed to be 35 to 40 mm which is normal.

In 40 % cases it was noted to be 41 to 50 mm.

In 20 % cases variation was observed and location was recorded to be 25 mm.

**On right side –**

Mean = 4.40 and SD = 0.65, so the average distance is  $4.40 \pm 0.65$  cm

In 40 % cases it was observed to be 35 to 40 mm which is normal.

In 50 % cases it was noted to be 41 to 50 mm.

In 10 % cases variation was observed and location was recorded to be more than 50 mm.

**5. Discussion:**

Embryonic vascular development of lower limb has been discussed as a basis for variant arterial anatomy. The axis artery of lower limb grows out from the dorsal root of umbilical artery (Fifth lumbar inter segmental artery). The arterial trunk accompanies the sciatic nerve and runs distally along the dorsal surface of the thigh, knee and leg. It terminates in the plantar capillary plexus which communicates with the dorsal vascular network through the sinus torsi. Femoral artery develops from a capillary plexus in the ventral aspect of the thigh, it establishes communication proximally with the external iliac artery, and distally joins with the axis artery.[4]

The internal diameter of 40 adult femoral arteries were measured by using radial calipers. The average internal diameter of the femoral artery recorded in this study both on right and left side ranged between 6mm to 8mm which is in accordance to the finding obtained by contrast angiographic technique of the blood vessels, when the arterial catheter is passed in the femoral artery the average diameter is cited as 6 to 10 mm, these blood vessels are visualized in the infra inguinal occlusive diseases which are indicated in peripheral vascular diseases and chronic arterial femoro popliteal occlusive diseases (Richard 2006).[5]

The level of origin of profundafemoris artery was varying from 25mm to 60mm from the midpoint of the inguinal ligament. The profundafemoris artery in this study originated mostly from the posterolateral side of the femoral artery as is mentioned by Bannister (1995). The average distance of origin of profundafemoris artery from the midpoint of inguinal ligament was 41 mm or 4.1 cm, that was more than 35 mm or 3.5cm

**6. Conclusion :**

The knowledge of the internal diameter of femoral artery at the femoral triangle is useful to surgeons and interventional radiologists as this artery is used in certain clinical procedures like cardiac catheterization, trans arterial chemo embolization in the treatment of malignancy, arteriography in peripheral vascular diseases. The knowledge of the site of origin of profundafemoris artery helps in avoiding iatrogenic femoral arteriovenous fistula or severe secondary haemorrhage, while

performing femoral arterial puncture. The profunda femoris artery is used for arteriography, ultrasound, Doppler imaging and magnetic resonance imaging

**7. References**

1. Bannister, L.H; Berry, M.M; Collins, P. Gray's Anatomy. In: Cardiovascular system. 38th Edn.; Churchill Livingstone, Medical Division of Longman Group, UK Ltd. 1995, pp. 1566-8..
2. Siddharth P, Smith NL, Mason RA, Giron F. Variational anatomy of the deep femoral artery. *Anat Rec* 1985, 212 (2): 206–209.
3. Vuksanovic Bozagic A, Stefanivic N, Pavlovic S, Duraskovic R, Randelovic J. Analysis of deep femoral artery origin variances on fetal material, *Facta Universities: Medicine and Biology*, 2007, 14 (3): 112-116
4. A.K. Datta. Essentials of human embryology. In: Cardiovascular system. 5th edition, Current books international; 2005. p 196-197.
5. Richard, M. Stillman. Infra inguinal occlusive diseases. *E Medicine from WebMed*; [serial on line] 2006; p 8
6. Snell, R.S; *Clinical Anatomy of Medical Students*. 4th Edn. Little Brown and Co. Boston. (1992). p. 607
7. MB Samarawickrama ,BG Nanayakkara ,KWR Wimalagunaratna ,DGNishantha , UBWalawag; Branching pattern of the femoral artery at the femoral triangle: a cadaver study e; *Galle Medical Journal*, Vol 14: No. 1, September 2009, pp.31-34.
8. Dixit, D.P, et al; Variations in the Origin and Course of Profunda Femoris ; *J Anat. Soc. India* 2001; 50(1): 6-7.
9. Marina Baptist, et al ; Anatomical variations; The origin of profundafemoris artery, its branches and diameter of the femoral artery; *Professional Med J Sep* 2007; 14 (3): 523-527.