



Contents lists available at BioMedSciDirect Publications

## International Journal of Biological & Medical Research

Journal homepage: [www.biomedscidirect.com](http://www.biomedscidirect.com)



### Original Article

# Large Bone Defect, A Sequale Of Chronic Osteomyelitis: A Case Report Of Limb Salvage In Management Of Chronic Osteomyelitis Of Proximal Humerus In A 6 Year Old Child.

Sankara Rao Pinnamaneni <sup>a</sup>, Ch.V.S. Govindappa <sup>b</sup>, Vamsi Kondreddi <sup>c</sup>, Ranjith Kumar Yalamanchili <sup>d</sup>

<sup>a</sup> Associate Professor, <sup>b</sup> Professor, <sup>c</sup> Assistant Professor, <sup>d</sup> Post graduate, Department of Orthopaedics, Mamata Medical College, Khammam.

#### ARTICLE INFO

##### Keywords:

Chronic Osteomyelitis,  
Large bone defects  
Intramedullary k wire fixation.

#### ABSTRACT

Chronic Osteomyelitis in children is usually a consequence of acute form and its chronicity depends on virulence of the pathogen, immune response of the patient and treatment taken. Although acute form is prevalent in metaphyseal region, its chronic transformation can spread through entire length of bone and destroy all or part of it<sup>2</sup>. It further results in discharging sinuses and sequestrum formation. The sequestrum will maintain the length and alignment of the limb while the periosteum lays down new bone around it. At times, sequestrum may creep out of the sinus tract and an incomplete involucrum causes a large bony defect<sup>3</sup>. Management of such cases in children is often a potential challenging situation in view of constraints to choice of implants and growth cartilage proximity. We present a case of a child with similar scenario managed by intramedullary k wire fixation of fibular strut graft and its outcome.

© Copyright 2010 BioMedSciDirect Publications IJBMR -ISSN: 0976:6685. All rights reserved.

### 1. Introduction

Chronic osteomyelitis in children is usually a consequence of acute form and its chronicity depends on virulence of the pathogen, immune response of the patient and treatment taken<sup>1</sup>. Although acute form is prevalent in metaphyseal region, its chronic transformation can spread through entire length of bone and destroy all or part of it<sup>2</sup>. It further results in discharging sinuses and sequestrum formation. The sequestrum will maintain the length and alignment of the limb while the periosteum lays down new bone around it. At times, sequestrum may creep out of the sinus tract and an incomplete involucrum causes a large bony defect<sup>3</sup>. In addition, it has been shown that cytokines, such as interleukin-1 and tumor necrosis factor, present at the site of infection, are potent osteolytic

promoters<sup>4,5</sup>. Within the infected regions, vascular channels are compressed and obliterated by the inflammatory process leading to bony ischemia and form a large bony defects.

Limb salvage in reconstructing the large bony defects in children is a posing challenge owing to limitations of hardware options. The treatment options include : Vascularised fibular grafts<sup>6</sup>, Non vascularised Grafts<sup>7</sup>, Bone graft substitutes<sup>8</sup>, non-structural cancellous bone graft<sup>9</sup>, bone transport<sup>10</sup> and amputation<sup>11</sup>. Vascularised grafts are complicated by a low rate of primary union and a high rate of infection and thrombosis<sup>3,6,11</sup>. Non-structural cancellous bone graft and bone graft substitutes have poor cortical strength<sup>11</sup>. Bone transport in children is a technically demanding procedure having poor compliance in children<sup>9</sup>. The fibula's length, straight configuration, cortical support, and composite tissue make it ideal for the reconstruction of segmental long bone defects. It can be used to reconstruct defects of up to 10 cm<sup>12</sup>. Its size and relatively straight configuration allow it to be used within the humerus, forearm, clavicle, as well as in the tibia and femur.

\* Corresponding Author : Dr. Sankara Rao P, M.S, MCh(Ortho)

Associate Professor, Dept of Orthopaedics,  
Mamata General Hospital,  
Giriprasad Nagar, Khammam, A.P. 507002  
Ph: +91-9505142477

[vpneni@yahoo.com](mailto:vpneni@yahoo.com)

[orthovamsi@gmail.com](mailto:orthovamsi@gmail.com)

©Copyright 2010 BioMedSciDirect Publications. All rights reserved.

**CASE REPORT :**

A 5 year male child initially presented with history of pain over his right shoulder and mild pain at wrist following a fall in his school 8 Months ago. X ray of shoulder showed no Bony injury and he was applied a below elbow cast suspecting a physeal injury of distal radius by a local practitioner. Within 3 days the child developed severe swelling over his upper aspect of right Arm and shoulder region along with high grade fever. Cast was removed and treated symptomatically with intravenous antibiotics by a Paediatrician. After 1 week they performed incision and drainage over abscess at upper third of lateral aspect of the arm. A X ray taken after 1 month showed lytic lesions over proximal humerus. He was treated with intravenous antibiotics for 2 months followed by oral antibiotics for 2 months. Child continued to have draining sinus from the I&D site over upper third lateral aspect of arm. At 6th month he was prescribed intravenous antibiotics and within 3 weeks sinus healed. Patient presented to us with above history of 8 months duration, with limitation of function of right shoulder and for further management. There were no clinical signs of inflammation apart from frank abnormal mobility at proximal aspect of arm. X ray showed resorption of proximal diaphyseal segment [Fig 1]. Serological parameters revealed lymphocytosis, ESR was 40 and CRP was negative.

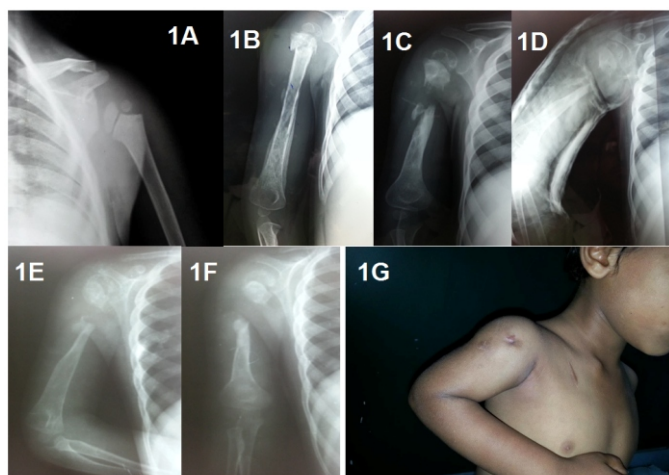


Fig 1- Case profile : 1A: X-ray at presentation 8 months ago. 1B: X-ray 1 month after treating with IV antibiotics and I&D. 1C: X-ray 5 months after initial presentation. 1D: X-ray at 6th month, after treating with antibiotics and application of cast. 1E and 1F : AP and Lateral views of humerus at 8months after presentation showing complete destruction of proximal diaphysis. 1G: Clinical picture of child showing healed sinus scars and instability of arm on movements at shoulder.

We have planned an autologous non vascularised cortical grafting from middle third shaft of fibula. Intraoperatively, bone ends were found to be sclerotic with fibrous tissue in the bone defect region. After freshening the edges of bone fragments, fibrous tissue was nibbled out and a 6 cm fibular strut graft was taken from middle third of shaft of ipsilateral fibula. A 1.5mm k-wire is used as an intramedullary nail and passed from distal humerus to distal fragment and then through the fibular graft and further to proximal fragment of humerus [ Fig 2 ]. The bony defect was filled and wound closed in layers. Post operatively, fixation was stabilised using an adhesive bandage applied over arm and elbow to support distal fragment from being pulled down due to gravity. Suture removal was done on 10th post operative day and surgical wound healed well over donor area of leg and surgical site of arm. Patient was discharged with a U-slab and was advised monthly follow up.

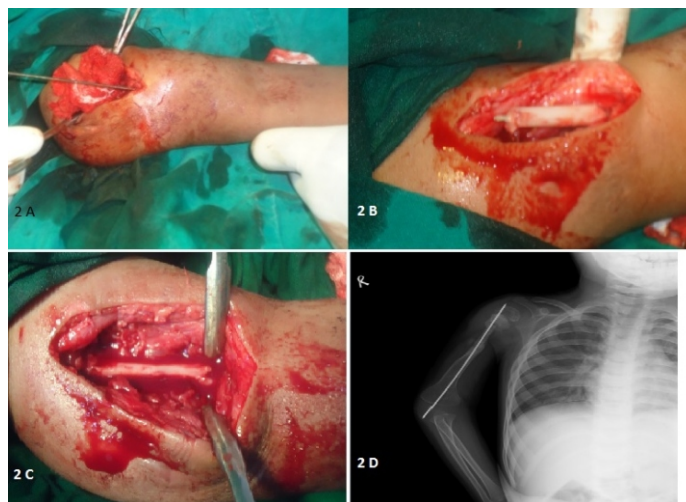


Fig 2 : 2A – K-wire passed retrogradely ; 2B- Fibular strut graft passed through K-wire ; 2C- intraoperative picture showing fibular strut graft fixed to proximal humerus; 2D- Post OP X ray of humerus with K-wire and fibular strut graft.

Follow-up X ray at 4 weeks showed callus and there were no signs of non-union clinically. Child was started with maximum possible active range of movement exercises at shoulder. At 8 weeks, there was good callus and hence k-wire removed and patient had good functional outcome. At 18 months of final followup, child had complete union without any signs of infection, and good functional outcome without any neurological deficits. Donor fibula showed regrowth without any further donor site morbidity.

**4. DISCUSSION :**

Chronic osteomyelitis is a cause of considerable morbidity, particularly in the juvenile skeleton when it may lead to limb-length inequality secondary to growth arrest<sup>13</sup>. Despite advances in treatment, occasional cases of osteomyelitis are still difficult to resolve, especially those with bone defects. Eradication of the infection requires excision of all infected bone followed by prolonged administration of antibiotics. Usually, sequestrectomy is delayed until a bridging involucrum has formed, but when the sequestrum is protruding through the skin and there is a large amount of pus or the patient is systemically compromised, urgent sequestrectomy may be required resulting in a considerable longitudinal bony defect. Severe damage to the periosteum may prevent an involucrum from forming.<sup>3</sup>

The filling of a bony defect after infection can be a challenge. A high rate of complications and a rate of primary union of as low as 48% have been reported in management of bone defects following chronic osteomyelitis<sup>6</sup>.

Although vascularised fibular grafts do not rely on revascularisation and therefore should be incorporated, they are more prone to thrombosis of grafted vessels<sup>12,14</sup>. Non-vascularised fibular grafts are less technically demanding and have been reported with good union in defects less than 10cm particularly in immature skeleton<sup>12</sup>.

Donor-site morbidity is also common. Gore et al<sup>15</sup> reported that “most patients will have subjective complaints and mild muscle weakness after removal of a portion of the fibula”. Excision of a segment of fibula has been shown to lead to proximal migration of the lateral malleolus and accompanying valgus tilt, these being statistically linked. In the present case, we do not encounter with any donor site morbidity.

Osteomyelitis-induced bone defects, which cause massive morbidity is uncommon in developed countries and hence does not have much focus of evidence based treatment protocols. Our novel report shows that these can be treated successfully, often by relatively simple methods. In the absence of ongoing infection, the use of fibular grafts harvested subperiosteally in the management of defects of long bones is a relatively straightforward procedure, requiring no microsurgical expertise. Immediate bony stability is achieved by the use of an intramedullary K-wire. Bone transport or vascularised grafting are more reliable but are more complex solutions particularly in remote rural areas, where these cases are more encountered due to poverty.

## 5. Reference

- [1] Tudisco C, Farsetti P, Gatti S, Ippolito E, Influence of chronic osteomyelitis on skeletal growth : Analysis at maturity of the 26 cases affected during childhood. *J. Paediatr. Orthop.*, 1991,11,358-363.
- [2] Chung Y.K., Chung S. Ipsilateral island fibula transfer for segmental tibial defects : Antegrade and retrograde fashion. *Plast. Reconstr. Surg.*, 1998,101,375-382.
- [3] Daoud A, Saighi-Bouaouina A. Treatment of sequestra, pseudarthrosis and defects in the long bones of children who have chronic haematogenous osteomyelitis. *J Bone Joint Surg [Am]* 1989;71-A:1448-68
- [4] Manolagas S C. Birth and death of bone cells: basic regulatory mechanisms and implications for the pathogenesis and treatment of osteoporosis. *Endocr Rev.* 2000;21:115-137.
- [5] Klosterhalfen B, Peters K M, Tons C, Hauptmann S, Klein C L, Kirkpatrick C J. Local and systemic inflammatory mediator release in patients with acute and chronic posttraumatic osteomyelitis. *J Trauma.* 1996;40:372-378.
- [6] Han C-S, Wood MB, Bishop AT, Cooney WP 3rd. Vascularised bone transfer. *J Bone Joint Surg [Am]* 1992;74-A:1441-9.
- [7] Steinlechner CWB, Mkandawire N. C. Non-vascularised fibular transfer in the management of defects of long bones after sequestrectomy in children. *J Bone Joint Surg Br Sep* 2005; Vol. 87-B; 9; 1259-1263.
- [8] Enneking WF, Eady JL, Burchardt H. Autogenous bone grafts in the reconstruction of segmental skeletal defects. *J Bone Joint Surg [Am]* 1980;62-A:1039-58.
- [9] Cattaneo R, Catagni M, Johnson EE. The treatment of infected nonunions and segmental defects of the tibia by methods of Ilizarov. *Clin Orthop* 1992;280:143-52.
- [10] Stevenson AJ, Stolbrink M, Moffatt D, Harrison W J, Cashman J, TREATMENT OF BONE DEFECTS IN CHILDREN CAUSED BY CHRONIC HAEMATOGENOUS OSTEOMYELITIS: A RETROSPECTIVE REVIEW OF 57 PATIENTS, *Bone Joint J* 2013; Vol:95-B; 75
- [11] Daoud A, Saighi-Bouaouina A. Treatment of sequestra, pseudarthrosis and defects in the long bones of children who have chronic haematogenous osteomyelitis. *J Bone Joint Surg [Am]* 1989;71-A:1448-68.
- [12] Yajima H, Tamai S, Mizumoto S, Inada Y. Vascularized fibular grafts in the treatment of osteomyelitis and infected nonunion. *Clin Orthop Relat Res.* 1993;256-264.
- [13] Bates J. Bone overgrowth in chronic osteomyelitis in children. *Procs Association of Surgeons of East Africa conference* 2003.
- [14] Minami A, Kasashima T, Iwasaki N, Kato H, Kaneda K. Vascularised fibular grafts. *J Bone Joint Surg [Br]* 2000;82-B:1022-5.
- [15] Gonzalez-Heranz P, del Rio A, Burgos J, Lopez-Mondejar JA, Rapariz JM. Valgus deformity after fibular resection in children. *J Paed Orthop* 2003;23:55-9.