



Case report

Endometrial osseous metaplasia : A case report

Dr . B N Kishore kumar^a, Dr. Deepak Das^b, Dr. Shivaraj H.G.^c

Professor and HOD , Department of Radiodiagnosis, Sri Devaraj urs medical college, Kolar, India

Post graduate Resident, Department of Radiodiagnosis, Sri Devaraj urs medical college, Kolar, India

1.Post graduate Resident , Professor and HOD , Department of Radiodiagnosis, Sri Devaraj urs medical college, Kolar, India

ARTICLE INFO

Keywords:

Osseous metaplasia
Endometrium
Sonography
Infertility

ABSTRACT

Objective: Osseous metaplasia of endometrium is a rare clinical entity with presence of mature or immature bone in endometrium. Most of the cases present with secondary infertility following abortion, chronic endometritis. Case History : We report a case of osseous metaplasia of endometrium in a 32-year-old patient with a history of infertility following an abortion. Conclusion : Endometrial osseous metaplasia is a rare cause of infertility. Its recognition by sonography is an important step for its adequate management. It is important to differentiate it from intra uterine contraceptive device, foreign body and mixed müllerian tumor of endometrium.

© Copyright 2010 BioMedSciDirect Publications IJBMR -ISSN: 0976:6685. All rights reserved.

1. Introduction

Osseous metaplasia of the endometrium results from the transformation of non-osseous connective tissue into mature or immature bone. Nearly 80 cases have been reported in the literature. In most of the reported cases, ossification of endometrium was followed by an abortion and patients present with infertility [1,2,3,4].

Its clinical presentation may include vaginal bleeding, leucorrhoea and pelvic pain. Various theories have been proposed and the accepted theory is metaplasia of the stromal cells into osteoblastic cells that produce mature bone [3,4,5].

2. Case report

A 32-year-old woman gravida 0, para 1 presented with history of secondary infertility. She was eager to conceive. Routine gynecological examination was negative. She was referred for routine pelvic sonography. Trans-abdominal pelvic sonography revealed normal sized retroverted uterus. Linear hyper-reflective area was noted in endometrial cavity (Fig 1). Myometrial echoes were normal. Both ovaries were normal. Transvaginal sonography was done which revealed an irregular hyperechoic area in endometrial cavity with dense shadowing (Fig 2 and 3). A provisional diagnosis of endometrial osseous metaplasia was made which was confirmed by hysteroscopy. Osseous tissue was removed which was confirmed by histological

examination. Laboratory investigations which included complete blood count, urine analysis, serum calcium and phosphorus and parathyroid hormone level were within normal limits.

Fig 1. Trans abdominal sonography : show a linear hyperechoic area in endometrial cavity

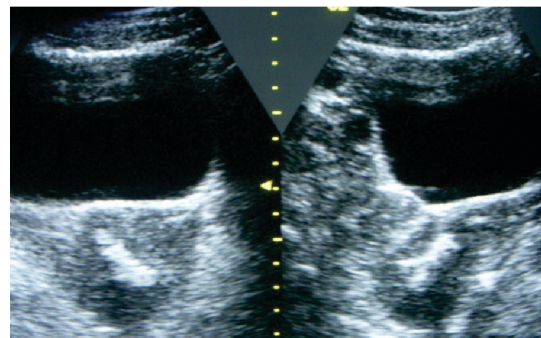
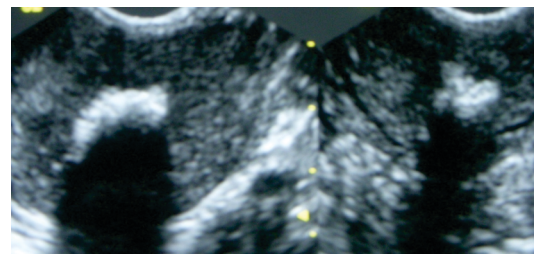


Fig 2. Transvaginal sonography reveals irregular hyperechoic area with shadowing in the endometrial cavity

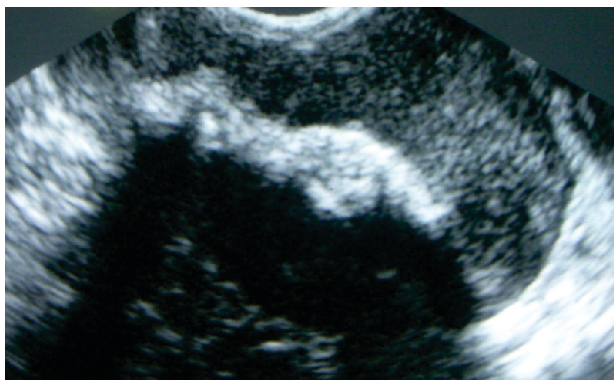


* Corresponding Author : Dr. B N Kishore Kumar

Professor and HOD,
Department of Radiodiagnosis
Sri Devaraj urs medical college,
Kolar, India
E-mail: kishoreradiologist@gmail.com

© Copyright 2010 BioMedSciDirect Publications. All rights reserved.

Fig3. Tansvaginalsonography show an irregular hyperechoic area with shadowing in endometrial cavity



3. Discussion

Ossification of the endometrium is a rare clinical entity. It is also described by various other names such as endometrial ossification, ectopic intrauterine bone, and heterotopic intrauterine bone. [2],[5],[6]

In most of the reported cases, the osseous metaplasia of the endometrium was followed by a previous history of abortion. [1],[5] Majority of the patients are in the reproductive age group with history of first trimester abortion and have regular menstrual cycles in the post-abortive period. The time interval between the abortion and discovery of endometrial ossification varies from 8 weeks to 14 years in reproductive age group. [7] Common clinical presentations are menstrual irregularities, pelvic pain, dyspareunia, vaginal discharge, and secondary infertility.

Various theories have been described in the published literature in the pathogenesis of endometrial osseous metaplasia including dystrophic calcifications, ossification of post-abortive endometritis. Sonography plays a primary role in the diagnostic work-up [8, 9].

Echogenic linear structures, which are detected during routine study could represent foreign body, an intrauterine contraceptive device [10].

Radiologists should consider the possibility of endometrial ossification as a differential diagnosis.

4. Conclusion

Endometrial osseous metaplasia is a rare but treatable cause of infertility in which intrauterine bone acts as a contraceptive device. Sonography plays an important role in detecting this condition. Radiologists and gynecologists should be aware of this entity and complete removal of the bony spicules from the endometrial cavity by hysteroscopy regains the fertility.

5. References

- [1] Dutt S. Endometrial ossification associated with secondary infertility. *Br J Obstet Gynaecol* 1978;85:787-789.
- [2] Bhatia NN, Hoshiko MG. Uterine osseous metaplasia. *Obstet Gynecol* 1982;60:256-9.
- [3] Shroff CP, Kudterkar NG, Badhwar VR. Endometrial ossification--report of three cases with literature review. *Indian J Pathol Microbiol* 1985;28:71-74.
- [4] Lainas T, Zorzovilis I, Petsas G, Alexopoulou E, Lainas G, Ioakimidis T. Osseous metaplasia: case report and review. *Fertil Steril*.2004; 82(5):1433-1435
- [5] Hsu C. Endometrial ossification. *Br J Obstet Gynaecol* 1975;82:836-839.
- [6] Shimizu M, Nakayama M. Endometrial ossification in a postmenopausal woman. *J Clin Pathol*. 1997;50:171-172.
- [7] Bahçeci M, Demirel LC. Osseous metaplasia of the endometrium: a rare cause of infertility and its hysteroscopic management. *Hum Reprod* 1996;11:2537-2539.
- [8] Atay V, Pabuccu R, Duru NK, et al. The value of hysteroscopy in the diagnosis and treatment of residual intrauterine fetal bone fragments. *Turk J Fertil*.1998; 1:43
- [9] Ombelet W, Lauwers M, Verswijvel G, Grieten M, Hinoul P, Mestdagh G. Endometrial ossification and infertility: the diagnostic value of different imaging techniques. *Abdom Imaging*.2003; 28(6):893-896.
- [10] Basu M, Mammen C, Owen E. Bony fragments in the uterus: an association with secondary subfertility. *Ultrasound Obstet Gynecol*.2003; 22(4):402-406.