



Contents lists available at BioMedSciDirect Publications

International Journal of Biological & Medical Research

Journal homepage: www.biomedscidirect.com



Original article

Radiological study of range of Respiratory movements in Thin and Over weight individuals

***^aSreenivasulu Kanaka, ^bS.Sarah Nightingale, ^cSreedhar Babu. Kanaka, ^dAnil kumar Pulipati, ^eManisha R Gaikwad**

^aAssistant professor of Anatomy, Santhiram Medical college, Nandyal,

^bAssistant professor of Physiology, Mallareddy Medical college, Surarum, Hyderabad,

^cTutor, Dept of General Medicine, Santhiram Medical college, Nandyal,

^dAssistant professor of Anatomy, Santhiram Medical college, Nandyal,

^eProfessor of Anatomy, Santhiram Medical college, Nandyal.

ARTICLE INFO

Keywords:

Respiratory excursion

Position and descent of diaphragm

Emphysema

Hemipneumothorax of diaphragm

ABSTRACT

Back ground: The study is taken up because it is interesting to know about the physiological variations in the position of the diaphragm according to phase of ventilation, body built and position. **Clinical importance** in the position of the diaphragm related with hemipneumothorax of diaphragm and emphysema of the lungs. **Aims and Objectives:** to study the changes in the position of the diaphragm and movements of respiration during phase of ventilation in thin and overweight individuals which includes both males and females. **Methods:** We have selected 50 individuals in the age group 19-40yrs. All the study groups are taken from Santhiram medical college, particularly students and staff. Two chest x- ray postero-anterior views are taken - after forced inspiration and forced expiration. **Results:** In thin individuals range of movements of diaphragm varies from 5-6 cms but in over weight individuals it varies from 2.5-4cms. Height of right and left domes of diaphragm in thin individuals are 2.5cms higher when compared to overweight individuals. Elevation of ribs are 0.25cms lesser in thin individuals. **Conclusions:** All the range of respiratory movements are lower in thin individuals when compared to overweight individuals. It indicates that respiratory excursion is more in overweight individuals. It is interesting to note that in emphysema of lung the height of the diaphragm lies at a lower level.

©Copyright 2010 BioMedSciDirect Publications IJBMR -ISSN: 0976:6685. All rights reserved.

1. Introduction

The diaphragm is a curved musculofibrous sheet that separates the thoracic from abdominal cavity. The positions of the domes or cupulae of the diaphragm are extremely variable as they differ on body built and phase of ventilation. Thus the diaphragm will be higher in short fat people than in tall, thin people and overinflation of the lung, as occurs for example in emphysema, causes marked depression of the diaphragm[1-3]. Usually after forced expiration the right cupola is at the level anterior with the fourth costal cartilage and therefore right nipple, whereas the left cupola lies approximately one rib lower. With maximal inspiration, the cupola will descend as much as 10 cm and on plain chest radiograph the dome coincides with the tip of the sixth rib[4-7]. (table 4&5)

In supine position the diaphragm will be higher than in the erect position and when the body is lying on one side, the dependent diaphragm will be considerably higher than the uppermost one[2,4-6].

At full inspiration the right hemi diaphragm is found at the sixth rib anteriorly on postero-anterior chest radiograph. The left hemi diaphragm is 1.5-2.5 cm lower than the right. Unilateral paralysis may be seen as a raised hemi diaphragm on a chest radiograph[2,7].

The action of the diaphragm as inspiratory muscle depends, apart from other factors, upon its height in the thorax before the contraction starts. The higher thoracic height performs better inspiratory excursion. The diaphragm acts best as inspiratory muscle in the recumbent position, particularly when the foot end of the bed is raised and works least in sitting position with the relaxed anterior abdominal wall[4].

* Corresponding Author : Dr.Sreenivasulu.K,
H.No- 87-1377-13, Seshadri Nagar,
Near Nandyal check post, Kurnool-2,
Andhra Pradesh (State), India. Pin- 518002.
Email: sreenivas.knk@gmail.com

Diaphragm is the principle muscle of inspiration. total surface area of the adult diaphragm is about 270 sq cm. therefore, out of 500 ml of tidal air about 400 ml of air is drawn into the lungs in quiet inspiration by the descent of the diaphragm alone.

Average range of movement of diaphragm in quiet breathing is about 1.5 cm. Absolute range of movement in deep breathing varies between 6 cm and 10 cm- pump handle movement[4].

2.Material and Methods:

We have selected 50 individuals which includes 25 thin(B.M.I. 16-18.5 Kg/M²) and remaining 25 overweight(B.M.I. 25-30 Kg/M²) individuals. Among them 30 were male remaining 20 were females. We have calculated the range of movements of diaphragm along mid clavicular plane and mid axillary plane after forced inspiration and after forced expiration. we also have calculated the range of movements of ribs and particularly 1st rib during forced inspiration.

3.Results:

Movements of diaphragm after forced inspiration and forced expiration varies between 5-6 cm in overweight individuals, 2.5-4 cm in thin individuals(table1,skiagrams 2&4). The levels of diaphragm after forced inspiration and forced expiration corresponding with 8th rib posteriorly and 6th rib anteriorly close to lateral margin of sternum in overweight individuals, 7th rib posteriorly and 5th rib anteriorly close to lateral margin of sternum in thin individuals(table2,skiagrams1,2,3&4). Movements are more along mid axillary plane in both thin and overweight individuals(skiagrams2,4). Range of elevation of ribs is 0.5 cm in fat individuals, 0.25 cm in thin individuals(table3,siagrams1,2,3&4). When compared to males and females position of diaphragm is slightly lower but in both movements varies according to body built. Particularly these values are observed in south indian people.

Table 1:Descent of diaphragm along anatomical planes after forced inspiration and forced expiration in present study

Descent of diaphragm	In thin individuals	In fat individuals
Along mid clavicular plane	2.5cm	5cm
Along mid axillary plane	4	6cm

Table2: Position of diaphragm in thin and fat individuals according to phases of ventilation in present study

Position of diaphragm	In thin individuals	In fat individuals
After forced inspiration	7th rib posteriorly	8th rib posteriorly
After forced expiration	6th rib posteriorly	7th rib posteriorly

Table 3: Range of movements of ribs in the present study

	In thin individuals	In fat individuals
Range of Movements of ribs	0.25 cm	0.5 cm

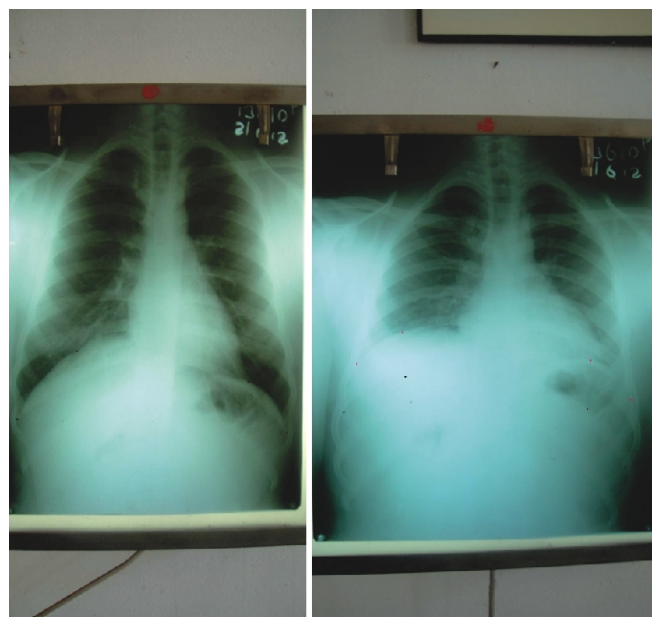
Table 4: Descent of diaphragm according to various authors[2,4,5&6]

Asim kumar dutta	6-10 cm
Gray	6-10cm
A.Halim	1 rib lower
Present study	2.5-6(south indian people)

Table 5: Position of diaphragm according to phase of ventilation by various authors[2,4,5&6]

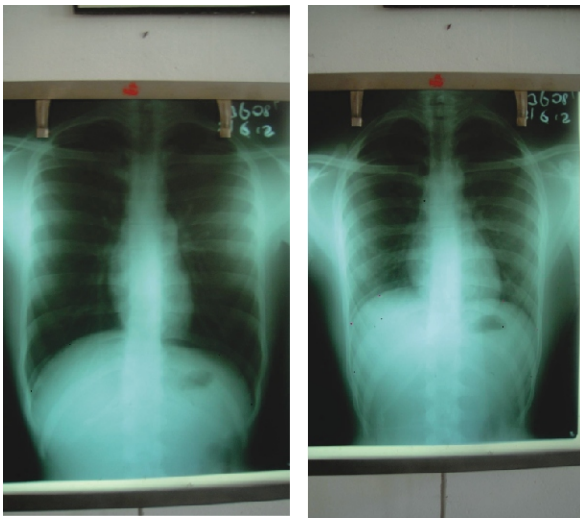
Asim kumar dutta	6th rib anteriorly
Gray	6th rib anteriorly
A.Halim	6th rib anteriorly
Present study	6th rib anteriorly ,8th rib posteriorly after forced inspiration in fat people 5th rib anteriorly, 7th rib posteriorly after forced expiration in thin people

Figure



skiagram 1(left)- showing black dots indicating position of right and left domes of diaphragm after forced inspiration in over weight individual.

skiagram 2(right)- showing red dots indicating position of right and left domes of diaphragm after forced expiration in over weight individual. distance between red and black and red dots indicating descent of diaphragm.



skiagram 3(left)- showing black dots indicating position of right and left domes of diaphragm after forced inspiration in thin individual.

skiagram 4(right)- showing red dots indicating position of right and left domes of diaphragm after forced expiration in thin individual. distance between red and black and red dots indicating descent of diaphragm.

4. Discussion

Skiagraphy shows that the height of the diaphragm in the thorax varies considerably with the position of the body. It stands highest when the body is horizontal and the patient on his back, and in this position it performs the largest respiratory excursions with normal breathing. When the body is erect the dome of the diaphragm falls, and its respiratory movements become smaller. The dome falls still lower when the sitting posture is assumed, and in this position its respiratory excursions are smallest. These facts may, perhaps, explain why it is that patients suffering from severe dyspnoea are most comfortable and least short of breath when they sit up. When the body is horizontal and the patient on his side, the two halves of the diaphragm do not behave alike. The uppermost half sinks to a level lower even than when the patient sits, and moves little with respiration; the lower half rises higher in the thorax than it does when the patient is supine, and its respiratory excursions are much increased. In unilateral disease of the pleura or lungs analogous interference with the position or movement of the diaphragm can generally be observed skiagraphically.

It appears that the position of the diaphragm in the thorax depends upon three main factors, viz.: (1) the elastic retraction of the lung tissue, tending to pull it upward; (2) the pressure exerted on its under surface by the viscera; this naturally tends to be a negative pressure, or downward suction, when the patient sits or stands, and positive, or an upward pressure, when he lies; (3) the intra-abdominal tension due to the abdominal muscles. These are in a state of contraction in the standing position and not in the sitting; hence the diaphragm, when the patient stands, is pushed up higher than when he sits[5].

External intercostal muscles on one side of the body along with contralateral internal intercostal muscles that have the same fibre direction and on the same side of the axis of rotation act synergistically to elevate the ribs. Eventually the body of sternum moves forwards during elevation of ribs at sterno-manubrial joint, and then swing backward in expiration. This is known as pump handle movement.

The first rib and manubrium sterni form a rigid unit and do not move in quiet breathing. In forced inspiration, however, these are elevated. The second to sixth ribs and their costal cartilages slope downwards and forwards. Hence, their elevation results forward and upwards movements of the body of sternum and increases the antero-posterior diameter. The seventh to tenth ribs slope downward and forward, but their costal cartilages are directed upward and medially to reach the sternum. As a result the elevation of these ribs produces a backward movement of the sternum at the sterno-manubrial joint and diminishes antero-posterior diameter.

The transverse diameter is increased by two methods, passive and active. Passive increase is found in upper six ribs. These ribs while moving around the oblique axis of the neck of the ribs to increase the antero-posterior diameter, also wide partly the transverse diameter. The passive increase is facilitated by the curved nature of the articular surfaces of the costo-transverse joint.

Active increase is observed in the seventh to tenth ribs, where movement takes place around an antero-posterior axis from costo-vertebral to costo-transverse joints. This produces elevation of the middle of the rib by outward twist, which resembles lifting of the handle of a bucket: hence called bucket handle movement.

The vertical diameter of the thorax is increased by the descent of the diaphragm producing piston movement[4,6].(table 4, skiagrams 2&4))

In patients with hemiplegia or hemiparesis, asymmetry of the hemidiaphragm is more common than in a control group. This is due to elevation of the left hemidiaphragm in left sided weakness. Unilateral pneumonia seems to occur more frequently on the left side in left hemiparesis and on right in right sided weakness[7].

5. Conclusions

Position, descent of the diaphragm, elevation of the ribs are more in fat individuals when compared to thin individuals particularly south Indians. The values are lower when compared to other authors except A. Halim [8]. No significant change is observed in females except the diaphragm at a slightly lower level in comparison to males and left dome is not lower than 2cm when compared to right dome.

No Conflict of interest statement by Authors

Article title: Radiological study of range of Respiratory movements in Thin and Over weight individuals

Authors: Dr. Sreenivasulu.K*, Dr. S.Sarah Nightingale**,Dr. Sreedhar Babu.K***, Dr. Anil Kumar.P****,Dr. Manisha R Gaikwad*****

None of the authors of the above manuscript has declared any conflict of interest within the last three years which may arise from being named as an author on the manuscript.

6. References

- [1] Alfred P. Fishman-One hundred year of chronis pulmonary diseaseAmerical Journal of Respiratory and Critical Care Medicine.2005; Volume 171, page no: 941-948.
- [2] Gray's anatomy 39th edition, page no's- 1081,1082.
- [3] Vincent coltin, Nathalie Freymond Jean Cabane and Jean Fancois Cordier-combined pulmonary fibrosis and emphysema syndrome in a patient age 28 years with severe systemic sclerosis the Journal of Rheumatology. 2011; Volume 38, 2082-2083.
- [4] Asim Kumar Dutta -Essentials of human anatomy , 7th edition,2006; page no:17,18&153.
- [5] Gray's anatomy 38th edition, page no's- 817
- [6] Indu Khurana's text book of medical physiology,1st edition, page no:404.
- [7] Korcgyn AD, Hermann G and Don R. Diaphragmatic involvement in hemiplegia and hemiparisis Journal of Neurology, Neurosurgery and Psychiatry with Practical Neurology.1969December;32(6):588-590.
- [8] Halim A.Surface and Radiological Anatomy, Second edition,2004.