



Contents lists available at BioMedSciDirect Publications

## International Journal of Biological & Medical Research

Journal homepage: [www.biomedscidirect.com](http://www.biomedscidirect.com)



### Case report

## Neural Sheath Liposarcoma

Siddaram.N.Patil<sup>a</sup>, Rajsekhar Reddy K<sup>b</sup>, Ranjith K Yalamanchili<sup>c</sup>

<sup>a</sup> Professor, Dept of Orthopaedics, Mamata medical College, Khammam

<sup>b,c</sup> Post Graduate, Dept of Orthopaedics, Mamata Medical College, Khammam

#### ARTICLE INFO

##### Keywords:

Neural sheath  
Liposarcoma

#### ABSTRACT

Liposarcoma is a malignant mesenchymal tumor of the adipose tissue<sup>1</sup>. Liposarcomas most frequently arise from the deep-seated stroma rather than the submucosal or subcutaneous fat<sup>2</sup>. The most recent World Health Organization classification of soft tissue tumors recognizes five categories of liposarcomas: (1) well differentiated, which includes the adipocytic, sclerosing, and inflammatory subtypes; (2) dedifferentiated; (3) myxoid; (4) round cell; and (5) pleomorphic<sup>2-4</sup>. The anatomical distribution of liposarcoma appears to be partly related to the histologic type. Well-differentiated liposarcoma tends to occur in deep soft tissues of both the limbs and the retroperitoneum. Myxoid and/or round-cell liposarcomas and pleomorphic liposarcomas have a striking predilection for the limbs, and dedifferentiated liposarcoma occurs predominantly in the retroperitoneum<sup>4</sup>. Nerve involvement can be identified clinically with symptoms or signs of nerve compression, or by images showing direct contact of the tumor with a nerve on magnetic resonance imaging and then further defined at the time of surgery as tumor abutting (capsular involvement) or encasing a peripheral nerve<sup>5</sup>. We present a case of Liposarcoma involving the medial sural cutaneous nerve.

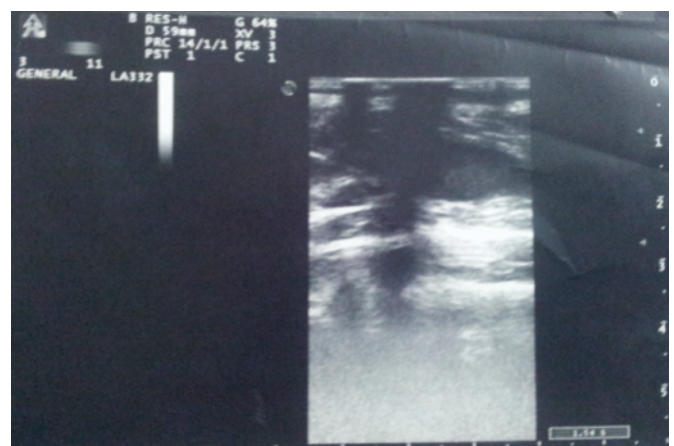
© Copyright 2010 BioMedSciDirect Publications IJBMR -ISSN: 0976:6685. All rights reserved.

### 1. Introduction

Liposarcoma is a malignant mesenchymal tumor of the adipose tissue<sup>1</sup>. Liposarcomas most frequently arise from the deep-seated stroma rather than the submucosal or subcutaneous fat<sup>2</sup>. The most recent World Health Organization classification of soft tissue tumors recognizes five categories of liposarcomas: (1) well differentiated, which includes the adipocytic, sclerosing, and inflammatory subtypes; (2) dedifferentiated; (3) myxoid; (4) round cell; and (5) pleomorphic<sup>2-4</sup>. The anatomical distribution of liposarcoma appears to be partly related to the histologic type. Well-differentiated liposarcoma tends to occur in deep soft tissues of both the limbs and the retroperitoneum. Myxoid and/or round-cell liposarcomas and pleomorphic liposarcomas have a striking predilection for the limbs, and dedifferentiated liposarcoma occurs predominantly in the retroperitoneum<sup>4</sup>. Nerve involvement can be identified clinically with symptoms or signs of nerve compression, or by images showing direct contact of the tumor with a nerve on magnetic resonance imaging and then further defined at the time of surgery as tumor abutting (capsular involvement) or encasing a peripheral nerve<sup>5</sup>. We present a case of Liposarcoma involving the medial sural cutaneous nerve.

### 2. Case

A 30 year old male patient presented to us with complaints of pain over back of knee and calf region since 12 months. Pain aggravated with exertion, walking and relieved on flexing the knee. He gives history of blunt injury to his upper calf 1 year ago. 6 months ago, he was started symptomatic treatment with analgesics for which he responded and was able to manage his daily activities. As the pain worsened and was not responding to analgesics, patient turned up for follow up. On examination, there was no palpable swelling even on resisted flexion of knee. He has superficial point tenderness over his lower popliteal region.

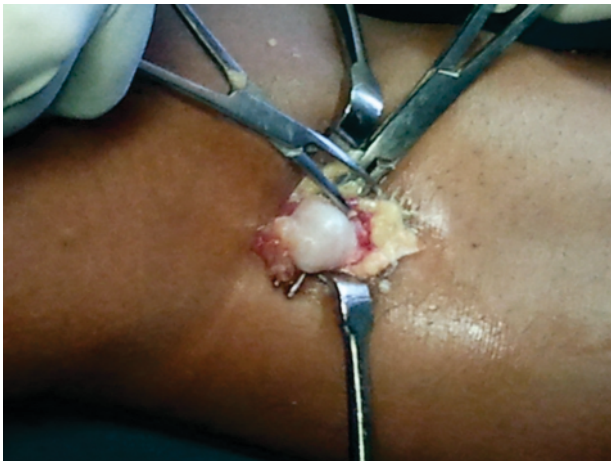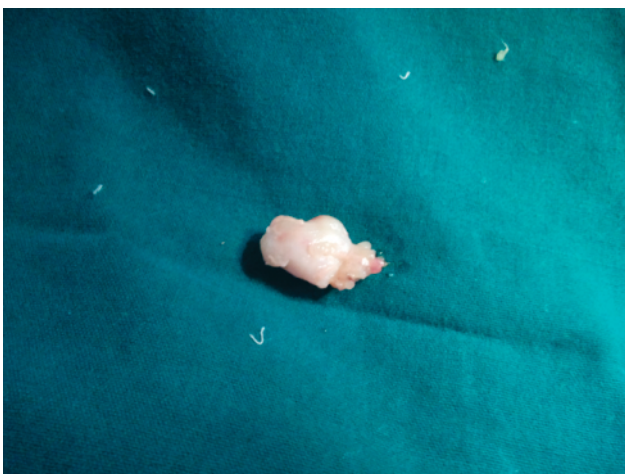
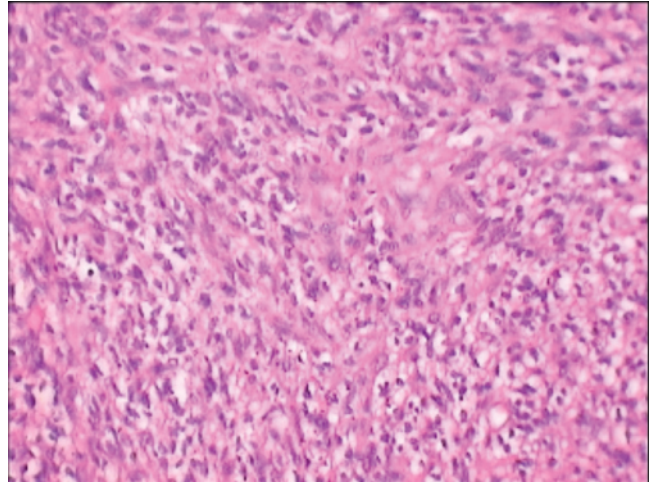


\* Corresponding Author : Dr. Siddaram.N.Patil

Dept of Orthopaedics,  
Mamata Medical College,  
Khammam.  
E.mail: drsnp\_2006@yahoo.co.in

**FIG 1 : Ultrasound of popliteal region over tenderness**

An ultrasound scan yielded well circumscribed, well defined hypoechoic lesion measuring 1.8 x 1 cm noted in popliteal fossa on posteromedial aspect in muscle compartment over the tender most point [FIG 1]. He was planned for excisional biopsy. Preoperatively tender point was marked and dissection in muscular plane over it has yielded a pearly white spherical swelling in the superficial cutaneous nerve sheath[FIG 2]. Marginal resection was done and specimen sent for histopathology[FIG 3]. Histopathology report confirmed well differentiated liposarcoma[FIG 4]. Patient was asymptomatic at 2nd monthly followup with healed surgical scar and improved functional outcome and normal gait. However, long term followup to check for recurrence is warranted.

**FIG 2: Dissection in surgical plane yielded the swelling in nerve sheath.****FIG 3 : Resected Gross specimen.****FIG 4 : Histopathology slide :Mature adipocytes and Lipoblasts.****3. Discussion :**

Liposarcoma has a predilection to the lower limbs of the body particularly the thighs, buttocks, groin, leg, and retroperitoneum<sup>6</sup>. On clinical examination of the calf and thigh, a major difficulty is when a swelling is deep to the deep fascia making it difficult to appreciate as a lump<sup>7</sup>. A general ultrasound with clinical symptoms would provide useful additional information. It is non-invasive and has an important role in differentiating a cystic and a solid swelling and its size thereby providing relevant information for further management<sup>8</sup>.

Liposarcomas are usually well-differentiated tumors with non-metastatic potential, especially if they are located in the extremities. Despite the huge size that these tumors can reach, large excision decrease local recurrence rate to almost zero. Studies have shown that well-differentiated liposarcoma located on the extremities does not require adjuvant therapy and overall they have prolonged survival and favorable prognosis<sup>9</sup>.

**5. References:**

- [1] Alejandro Garcia Morna, Juan Fermin Lozano Salinas, Federico Valdes Sepulveda, Homero Zapata, Lauro Salvador Gomez Guerra. Liposarcoma of the Spermatic cord; our experience and a literature review. *Actas Urologicas Espanolas* 2009; 33:811-5.
- [2] Christopher D, Unni K, Mertens F. Adipocytic tumors. In: WHO classification of tumors. Pathology and genetics: tumors of soft tissue and bone. Lyon, France: IARC, 2002; 19-46.
- [3] Fletcher D, Unni K, Mertens F. Liposarcoma of bone. In: World Health Organization classification of tumors. Pathology and genetics: tumors of soft tissue and bone. Lyon, France: IARC, 2002; 330.
- [4] Kempson R, Fletcher CD, Evans HL, Hendrickson MR, Sibley R. Malignant lipomatous tumors. In: Atlas of tumor pathology: tumor of the soft tissue. Washington, DC: Armed Forces Institute of Pathology, 2001; 217-238.
- [5] Kemp MA, Hinsley DE, Gwilym SE, Giele HP, Athanasou NA, Gibbons CL. Functional and oncological outcome following marginal excision of well-differentiated forearm liposarcoma with nerve involvement. *J Hand Surg Am.* 2011 Jan;36(1):94-100

- [6] Shokouh-Amiri MH, Hansen CP, Moesgaard F. Liposarcoma of the stomach. A case report. *Acta Chirurgica Scandinavica*. 1986;152:389-391.
- [7] Buchi RB Arumilli, Vinayagam Lenin Babu, and Ashok S Paul. Painful swollen leg – think beyond deep vein thrombosis or Baker's cyst. *World J Surg Oncol*. 2008; 6: 6.
- [8] Braunstein EM, Silver TM, Martel W, Jaffe M. Ultrasonographic diagnosis of extremity masses. *Skeletal Radiol*. 1981;6:157–163.
- [9] R Costea, E Vasiliu, NO Zarnescu, M Hasouna, and S Neagu. Large thigh liposarcoma–Diagnostic and therapeutic features. *J Med Life*. 2011 May 15; 4(2): 184–188.