

Contents lists available at BioMedSciDirect Publications

## International Journal of Biological & Medical Research

Journal homepage: [www.biomedscidirect.com](http://www.biomedscidirect.com)



### Original Article

## Radiological Study of Variations In The Pelvicalyceal System of Kidney

Pankaj R. Wadekar<sup>a</sup>, S. D. Gangane<sup>b</sup>

<sup>a</sup>Assistant Professor, Department of Anatomy, Government Medical College, Akola, Maharashtra, India (Ex. Asst Prof. G.M.C. Mumbai)

<sup>b</sup>Professor & Head, Department of Anatomy, G.M.C. Mumbai

#### ARTICLE INFO

##### Keywords:

Pelvicalyceal system  
Infundibular length  
Infundibular width  
Calices.

#### ABSTRACT

**Aims & Objective:** The present study has been undertaken to study the variations in renal pelvicalyceal system, to compare them with previous studies and to find their clinical implications. **Material & Methods:** A total of 200 kidneys (from 100 IVU films) were included in this study. The following parameters were measured 1) Lower Infundibular length, 2) Infundibular Width – Lower Infundibular Width (LIW), Middle Infundibular Width (MIW), Upper Infundibular Width (UIW), 3) Number of minor calyces and 4) Number of major calyces. **Result & Conclusion:** The obtained data showed that there were numerous variations not only in the numbers of calyces of kidneys but also in the infundibular length and width. The in-depth knowledge of pelvicalyceal anatomy of kidney will be of immense value to the clinicians of related specialties.

© Copyright 2010 BioMedSciDirect Publications IJBMR -ISSN: 0976:6685. All rights reserved.

### 1. Introduction

The variations of the renal collecting system and the developmental anomalies of kidney are numerous. The variations in the gross structure of the renal collecting system are probably as numerous as there are individuals and thus can be compared to fingerprints. The bilateral collecting systems present in any single individual are often similar but are rarely identical and not uncommonly, may be quite different even from one another.

The kidneys lie in the upper parts of the paravertebral gutters, posterior to the peritoneum, tilted against the structures on the sides of the lowest two thoracic and upper three lumbar vertebrae so that the anterior & posterior surfaces face anterolaterally & posteromedially respectively. The ureters are muscular ducts (25-30 cm long) with narrow lumina that carry urine from the kidneys to the urinary bladder. The renal pelvis is the flattened, funnel-shaped expansion of the superior end of the ureter. The apex of the renal pelvis is continuous with the ureter. The renal pelvis receives two or three major calyces. Anatomy textbooks frequently divide calyces into major and minor components. The usual description states that three major calyceal systems arise from the renal pelvis, subdividing into three to five minor calyces. For practical purpose all branches from the pelvis, whether single or multiple, are termed infundibula [1].

The knowledge of detailed calyceal anatomy is very essential for endourological procedures, for the selection of the best method of kidney stone treatment for a specific patient, for the better understanding and interpretation of standard Intravenous Urography [2]. The effect of pelvicalyceal anatomy on stone formation was not well evaluated up to date. If we consider that all the risk factors for stone formation are similar for both kidneys of a patient, it is very difficult to explain why a calculus is primarily formed in single calyx but not in other calyces of both kidneys, when metabolic factors are in operation. From this point of view, it is very logical to consider that different pelvicalyceal properties are the key factor for the lateralization of the stone and also constitute a risk factor for their etiology [3].

Intravenous Urography (I.V.U.) is the procedure of choice when anatomical details of the calyces, pelvis, or ureter are desired to be viewed. Urograms are best obtained in the expiratory phase. Variations in the excretory system are protean, and both radiologist and urologist often have difficulty in differentiating normal variations from early pathological changes [1].

On IVU the upper and lower major calyces are usually easily identified. It is at times difficult, however, to distinguish a middle major calyx from a minor calyx which arises from the pelvis or from another major calyx close to the pelvis. When seen end-on, a calyx appear as a circle with a less dense center. When it is superimposed over a portion of the pelvis, a circular shadow of double density is

\* Corresponding Author : **Dr. Pankaj R. Wadekar,**

Assistant Professor, Department of Anatomy,  
Government Medical College, Akola,  
Maharashtra (State), India, Pin: 444001  
Email: [drpankajwadekar@gmail.com](mailto:drpankajwadekar@gmail.com)  
[drpankajrw@rediffmail.com](mailto:drpankajrw@rediffmail.com)

formed and must not be mistaken for a calculus. The present study has been undertaken to study the variations in renal pelvicalyceal system, to compare them with previous studies and to find their clinical implications.

## 2. Material & Methods:

A total of 200 kidneys (from 100 IVU films) were included in this study. Diseased kidneys (e.g. with cystic kidney disease, anomalous, tumours etc.) were excluded from the study. The source of IVU films was from Radiology department at our Grant Medical College & Sir J.J. Group of Hospitals, Mumbai. The Study protocol was duly discussed and approved in the meeting conducted by Ethical Committee in 2006-2007. Microsoft Excel program was used to calculate the data. The data was collected using predesigned, pretested Pro-forma. Consent of each patient was taken on consent form.

The parameters measured were as follows:

### 1) Infundibular Width: -

Lower Infundibular Width (LIW),

Middle Infundibular Width (MIW),

Upper Infundibular Width (UIW),

LIW, MIW & UIW were measured at the narrowest point along their respective infundibular axis.

### 2) Lower Infundibular Length: -

This length is the distance measured from the most distal point at the bottom of the lower calyx to a midpoint of the lower lip of the renal pelvis [10].

### 3) Number of major calyces.

### 4) Number of minor calyces.

## 3. Result:

A total of 200 kidneys (from 100 IVU films) were studied. The results of infundibular measurements & of calyces are shown in graph 1 to 5 & and are discussed below.

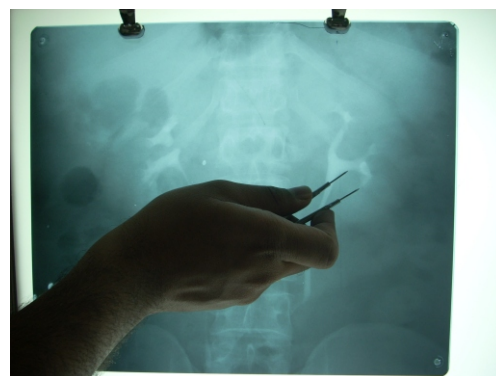**Table 1: Lower Infundibular Length (LIL)**

STUDIES	LIL
Kupeli Bora et al	1 to 25 mm
Yan K. F. et al	21.7 ± 6.9 mm (mean)
Madbouly K. et al	20.9 ± 6.56 mm (mean)
Li-ping Xie et al	25 to 47 mm
<b>Present study</b>	<b>10.2 to 30.9 mm</b>

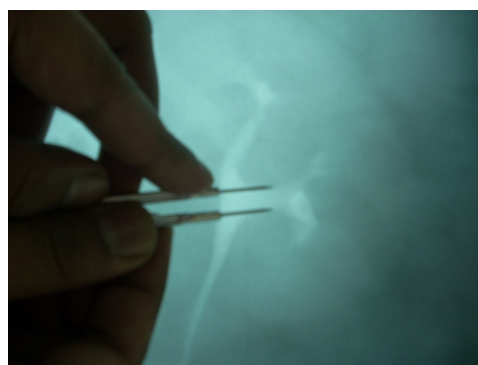**Table 2: Lower Infundibular Width (LIW)**

STUDIES	LIL
Madbouly K. et al	5.65 ± 2.34 mm (mean)
Yan K. F. et al	6.1 ± 2.3 mm (mean)
Li-ping Xie et al	3 to 13 mm
Sabnis R. B. et al	2 to 16 mm
Nabi G.	2 to 11 mm
Present study	3 to 10.5 mm

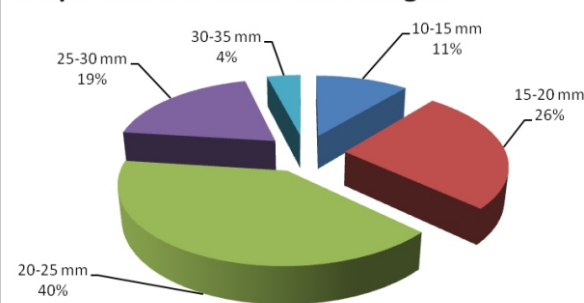
**Figure Measurement of LIL**

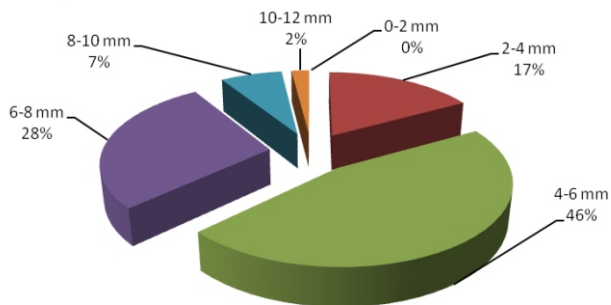
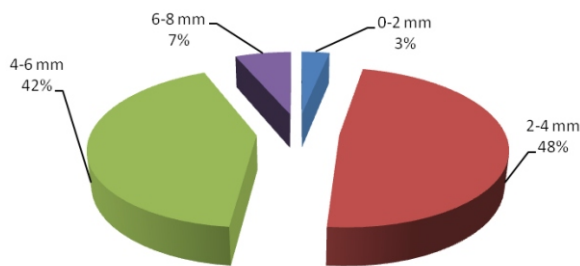
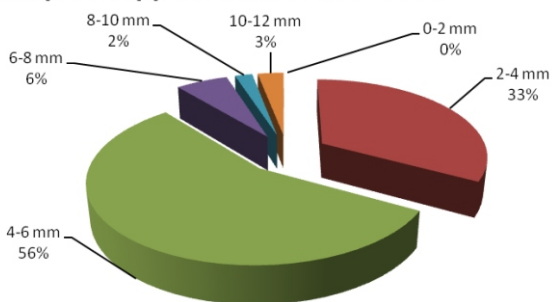
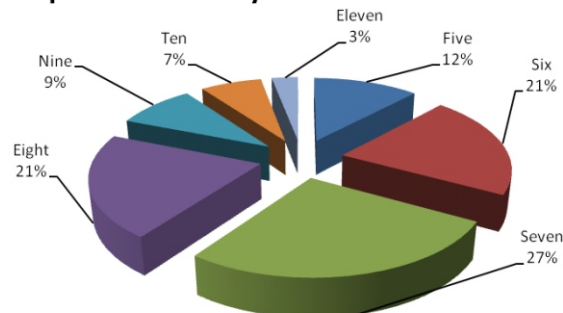


**Figure Measurement of LIW**



**Graph 1. Lower Infundibular Length**



**Graph 2. Lower Infundibular Width****Graph 3. Middle Infundibular Width****Graph 4. Upper Infundibular Width****Graph 5. Minor Calyces**

#### 4. Discussion:

##### Lower Infundibular Length (LIL):

In our present study the mean LIL was 21.23 mm. It varies from 10.2 to 30.9 mm and it was 20-25 mm in 40% (Graph no. 1). According to Sun Y. B. et al [4] and Gupta N. P. et al [5] the LIL was  $\leq 30$  mm in 60.87% & in 77% respectively. In similar studies, Madbouly K. et al [6] found that the LIL was  $\leq 30$  mm in 54.6%. Srivastava A. et al [7] found that in 54.55% the LIL was  $< 25$  mm. Another study was conducted by Sorensen C. M. et al [8] where they found that LIL was 21-30 mm in 48%, greater than 30 mm in 45%. (Table no. 1).

##### Lower Infundibular Width (LIW):

In our present study the mean LIW was 5.53 mm. It varies from 3 to 10.5 mm and it was 4-6 mm in 46% (Graph no. 2). According to Sampaio F. J. B. et al [9] and Li-ping Xie et al [10] the LIW was greater than 4 mm in 60.3% and 67% respectively. Our present findings are comparable with these studies (Table no. 2). Similarly, Gupta N. P. et al [5] found that in 75% of cases the LIW was 5 mm or more and the mean LIW was 6.75 mm. In similar studies, Sabnis R. B. et al [11] found that the LIW varies from 2 mm to 16 mm with 73 % having width of  $> 4$  mm. According to Madbouly K. et al [6] and Srivastava A. et al [7] the LIW was  $> 5$  mm in 41.7% & 25.76% respectively.

Middle Infundibular Width (MIW) and Upper Infundibular Width (UIW):

In study conducted by Kupeli Bora et al [3] the MIW varies from 1 mm to 10 mm (the mean was 2.71 mm) and the UIW also varies from 1 mm to 10 mm (the mean was 3.01 mm). In our present study the mean MIW was 4.0 mm. It varies from 2 to 7.4 mm. (Graph no. 3). The mean UIW was 4.66 mm. It varies from 2.2 to 11.3 mm. (Graph no. 4).

##### Minor Calyces:

In present study the number of minor calyces varies from 5 to 11 and most often 7 minor calyces were present (Graph no. 5). Kaye K. W. [12] stated that the numbers of minor calyces were 4 to 12 (most often 8). Sykes and David [13] found that the number of minor calyces varies from 5 to 20 (average 8 to 9). Similarly Harrison [14] reported that there were 8 to 9 minor calyces in kidney. Hollinshead [15] and Dyson M. [16] claimed that there were 7 to 8 minor calyces. Ningthoujam D. D. et al [17] found that the numbers of minor calyces were 8 to 18.

##### Major Calyces:

Fine and Keen [18] reported the presence of two major calyces in majority of cases and also the presence of third major calyx in some cases. Ningthoujam D. D. et al [17] reported that the number of major calyces varies from 2 to 3.

In present study the number of major calyces varies from 2 to 3. Two major calyces were present in 69%.

#### 4. Conclusion:

Present study was a sincere effort to identify variations in the pelvicalyceal system of kidney by radiological study. The obtained data showed that there were numerous variations not only in the numbers of calyces of kidneys but also in the infundibular length and width. Developments in endourology, percutaneous nephrolithotomy and techniques for retrograde percutaneous nephrostomy have rekindled interest in the anatomy of the renal collecting system. To perform these procedures safely and efficiently it is essential to have a clear understanding of pelvicalyceal anatomy and its variations. Thus the in-depth knowledge of pelvicalyceal anatomy will be of immense value to the clinicians of related specialties.

#### 6. References:

- Howard M. Pollack. Clinical Urography- an Atlas and Textbook of urological imaging. 1st edi. Vol. 1. Philadelphia, W B Saunders Co. 1990: 135-78.
- Hanif MS, Toori MH, Sheikh MA. Detailed calyceal anatomy for endourology. Pakistan J. Med. Res. 2004; 43(4): 184-87.
- Kupeli B, Tunc L, Acar C, et al. The impact of pelvicalyceal anatomical variations between the stone-bearing and normal contralateral kidney on stone formation in adult patients with lower calyceal stones. Int. Braz. J. Urol. 2006; 32(3): 22-32.
- Sun YB, Kim YH, Kwon CH. Anatomical factors that affect lower calyceal stone clearance after shock wave lithotripsy. Korean J. Urol. 1999; 40(11): 1440-44.
- Gupta NP, Singh DV, Hemal AK, et al. Infundibulopelvic anatomy and clearance of inferior calyceal calculi with shock wave lithotripsy. The Journal of Urology. 2000; 163: 24-27.
- Madbouly K, Sheir KZ, Elsobky E. Impact of lower pole renal anatomy on stone clearance after shock wave lithotripsy: fact or fiction?. Journal of Urology. 2001; 165: 1415-18.
- Srivastava A, Zaman W, Singh V, et al. Efficacy of extracorporeal shock wave lithotripsy for solitary lower calyceal stone: a statistical model. B.J.U. International. 2004; 93: 364-68.
- Sorensen CM, Chandhoke PS. Is lower pole calyceal anatomy predictive of extracorporeal shock wave lithotripsy success for primary lower pole kidney stone? Journal of Urology. 2002; 168: 2377-82.
- Sampaio FJB, Aragao AHM. Inferior pole collecting system anatomy: it's probable role in extracorporeal shock wave lithotripsy. Journal of Urology. 1992; 147: 322-24.
- Li-ping X, Shi-fang S. Radiographic anatomical insight into mechanism of lower calyceal stone evacuation following ESWL. Journal of Zhejiang University Science. 2000; 1(3): 347-51.
- Sabnis RB, Naik K, Patel SH, et al. Extracorporeal shock wave lithotripsy for lower calyceal stones: can clearance be predicted? British Journal of Urology. 1997; 80: 853-57.
- Kaye KW. Renal anatomy for endourological stone removal. The Journal of Urology. 1983; 130: 647-48.
- Syke D. The Morphology of renal lobulations and calyces, and their relationship to partial nephrectomy. Brit. J. Surg. 1964; 51(4): 294-304.
- Cunningham's Textbook of Anatomy. 11th edi. London, Oxford University Press. 1972: 503-56.
- Anatomy for Surgeons. Vol. 2. New York, A Hoeber-Harper Book. 1956: 540-42.
- Gray's Anatomy. 38th edi. Edinburgh, Churchill Livingstone. 1995: 1813-45.
- Ningthoujam DD, Chongtham RD, Sinam SS. Pelvicalyceal system in foetal and adult kidneys. J. Anat. Soc. India. 2005; 54(1): 1-11.
- Fine J, Keen EN. The arteries of the human kidney. J. Anat. 1966; 100(4): 881-94.