


Contents lists available at BioMedSciDirect Publications

International Journal of Biological & Medical Research

Journal homepage: www.biomedscidirect.com



Case Report

Residual non-union in a case of two and half year old child congenital pseudoarthrosis of ipsilateral tibia and fibula treated by intramedullary fixation with k-wire and allogenic cancellous strut graft

Dr. Siddaram N. Patil, M.S, M.ch(Ortho)

Professor, Dept of Orthopaedics, Mamata Medical College, General Hospital, Khammam, AP, India.

ARTICLE INFO

Keywords:

Congenital Pseudoarthrosis

Tibia and fibula

Non-union

Bone grafting vascularised bone graft

ABSTRACT

The pseudarthrosis usually develops during the first two years of life; however, there are reports of cases in which fractures developed before birth and reports of late-onset pseudarthrosis³. There is a strong association between Congenital pseudoarthrosis and Type I neurofibromatosis⁴. CPT develops in about 5.7% of patients with NF-I and 40% of patients with pseudoarthrosis were found to have NF-I^{4,5}. Main pathology is hyperplasia of fibroblasts with the formation of dense fibrous tissue at fracture site causing osteolysis, and persistence of pseudarthrosis⁵.

The difficulty in treating this condition occurs because of two factors. 1) Biologic: poor healing ability of the dysplastic segment of bone and 2) Mechanical: technical difficulty to fix small and osteopenic bone fragments in children without damaging the distal physis. A multitude of treatment protocols focusing on stimulating the healing process by using different bone grafting techniques were documented⁶. The graft materials most commonly used included osteoperiosteal graft, massive onlay graft, autogenous iliac crest bone graft, and vascularised bone graft.

© Copyright 2010 BioMedSciDirect Publications IJBMR -ISSN: 0976:6685. All rights reserved.

1. Introduction

Congenital Pseudoarthrosis of tibia and fibula is one of the most most perplexing and challenging problems in pediatric orthopaedics because of the difficulty in achieving and maintaining union. It is an uncommon entity with a reported incidence of 1:140,000 to 1:250,000 neonates^{1, 3}. It refers to nonunion of a fracture that develops spontaneously or after trivial trauma in a dysplastic bone segment of the lower third of tibial and fibular diaphysis. Congenital pseudoarthrosis of the fibula with or without ankle deformity often precedes or accompanies the same condition in the ipsilateral tibia². Sometimes it even develops between the time of successful bone grafting of a pseudoarthrosis of the tibia and skeletal maturity². The pseudoarthrosis usually develops during the first two years of life; however, there are reports of cases in which fractures developed before birth and reports of late-onset pseudoarthrosis³. There is a strong association between Congenital

pseudoarthrosis and Type I neurofibromatosis⁴. CPT develops in about 5.7% of patients with NF-I and 40% of patients with pseudoarthrosis were found to have NF-I^{4,5}. Main pathology is hyperplasia of fibroblasts with the formation of dense fibrous tissue at fracture site causing osteolysis, and persistence of pseudoarthrosis⁵.

The difficulty in treating this condition occurs because of two factors. 1) Biologic: poor healing ability of the dysplastic segment of bone and 2) Mechanical: technical difficulty to fix small and osteopenic bone fragments in children without damaging the distal physis. A multitude of treatment protocols focusing on stimulating the healing process by using different bone grafting techniques were documented⁶. The graft materials most commonly used included osteoperiosteal graft, massive onlay

* Corresponding Author :

E.mail: lavyav53@gmail.com

©Copyright 2010 BioMedSciDirect Publications. All rights reserved.

graft, autogenous iliac crest bone graft, and vascularised bone graft. The fixation methods also varied widely between cortical fixation using bone or metal plates, intramedullary rods of different types, external skeletal fixation, and lastly combination of external fixation augmented by intramedullary rods⁷. Although Bone morphogenetic proteins have shown clinical efficacy in the treatment of adult tibial nonunions and in spinal fusion, its logical application in cases of pseudoarthrosis along with corticocancellous allograft has not result in enhanced bone healing⁸.

2. Case Report

We report a two and a half year old female child with history of bowing of right leg since 2 months of age that was gradually increasing and deformity of lower third of right leg after trivial trauma at the age of 20 months. Child, who used to walk with support from 16 months of age was unable to stand or walk after trauma. Father is a known case of neurofibromatosis I and has multiple neurocutaneous lesions and cafe au lait spots. Child has multiple Caffé au lette spots with no neurocutaneous lesions. Anterior angulation of lower third leg with shortening of tibial component by 3cm and abnormal mobility in both anteroposterior and mediolateral planes with no stiffness of affected ankle joint were significant findings. [Fig 1]

X ray findings : Atrophic fracture ends of lower third tibia and fibula with obliteration of medullary canal and anterior angulation.

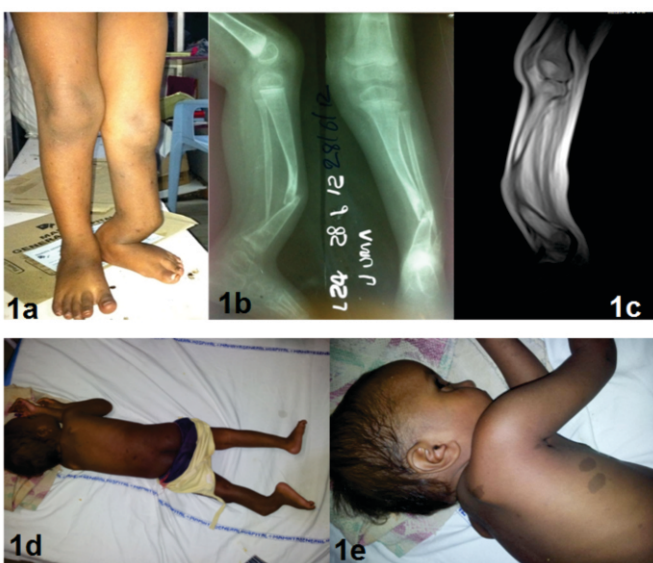

Fig 1: Clinical profile of a two and a half year old female child with congenital pseudoarthrosis tibia and fibula. **Fig 1a :** Clinical Photograph of Left leg bowing; **Fig 1b:** pre op X ray Left leg with dysplastic fracture ends and obliterated medullary canal of tibia and fibula; **Fig 1c:** MRI showing dysplastic ends and fibrous tissue at fractured ends with decreased signal intensity in the medullary canal at the pseudoarthrosis site suggesting obliteration of medullary canal; **Fig 1d and Fig 1e:** showing multiple Caffé au lette spots over trunk and abdomen.

The child was initially planned for excision of fibrosis and dysplastic ends of tibia and fixation. The abnormal part of tibia – dysplastic bony fractured ends and fibrous tissue was resected leaving a gap of 5cm. A thick allogeneous cancellous strut graft from the iliac crest of the child's father after due major cross matching the blood group was taken. The bone gap was reconstructed by passing a 1.5mm K-wire of 30cm length in a retrograde manner under c- arm guidance from distal tibia through talus, calcaneum to heel. A 1mm k wire is passed to fix the fibula after resecting the fibrous tissue and freshening the edges to provide internal splintage to the leg. The deformity was clinically corrected and there was no limb length discrepancy without neurovascular compromise. Post operatively child was immobilised in a above knee plaster cast. Suture removal was done after healing of surgical wound and there was no signs of infection. [Fig 2] Child was followed for up to 3 months, with check radiographs taken every monthly and there was no clinical signs of infection on inspection after removing cast. At the end of 3 months, there was no signs of bony union and the allogeneous cancellous graft was sclerotic. [Fig 3]

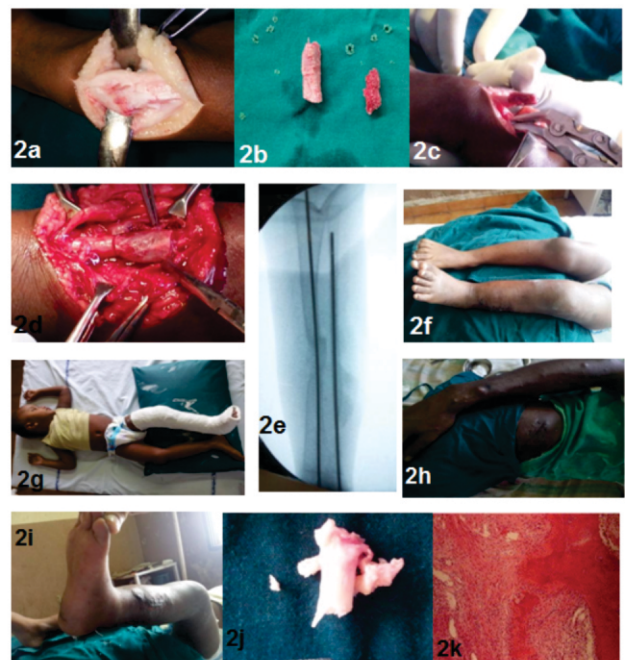

Fig 2: Surgical procedure of resection of pseudoarthrosis and intramedullary fixation with allogeneous cancellous bone graft. **Fig 2a- Intraoperative finding of fibrous tissue around dysplastic tibial ends at site of pseudoarthrosis of tibia;** **Fig 2b- Allogeneous Cancellous bone graft from child's father's Iliac crest;** **Fig 2c- Retrograde fixation of graft to resected tibia with a k-wire;** **Fig 2d- Intraop picture of allogeneous graft fixation with k-wires passed retrogradely;** **Fig 2e- C-arm picture showing correction of deformity with fixation of graft insitu;** **Fig 2f- Post operative picture showing deformity correction without limb length discrepancy by ensuing allograft sizing the resected specimen of tibia;** **Fig 2g- post operative splinting in above knee cast;** **Fig 2h- Clinical picture of parent with neurocutaneous lesions over the body showing surgical scar from iliac crest over allograft donation site;** **Fig 2i- Post-operative healed surgical scar with k-wires insitu;** **Fig 2j- resected gross specimen of sclerotic and dysplastic tibial ends over pseudoarthrosis site;** **Fig 2k- Histopathology slide of excised tissue show cellular proliferating fibrous tissue with immature bone is observed, 40 × resolution.**

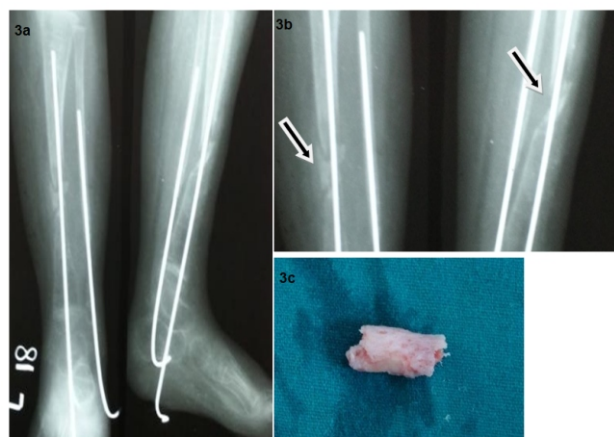


Fig 3: 3 months post surgery followup Scenario; Fig 3a- X-ray showing alignment with k-wires in situ and no signs of union and sclerosis of allograft; Fig 3b: Arrowmarks in the xray pointing to sclerosed and atrophied allograft; Fig 3c- The gross specimen of allograft after 3 months.

3. Discussion

The treatment goal for congenital pseudarthrosis of the tibia is to achieve bony union and avoid recurrent fracture and limb length discrepancy. The pathologic process of the disorder is the growth of abnormal, fibromatosis-like tissue either within the periosteum (dysplastic type) or within the endosteal/marrow tissue (cystic type), or the coexistence of both (mixed type) 9, 10. Complete excision of the abnormal tissue is necessary to treat the problem, evidenced by visualising normal bleeding and marrow cavity¹¹. Resection of the abnormal tissue, followed by fragment approximation, intramedullary nailing, and bone grafting, is a relatively easy procedure and is suggested as an initial treatment for congenital pseudarthrosis of the tibia¹². This treatment has a union rate of approximately 86%^{13, 14}.

In the present case, after resection of 4cm of dysplastic bone, reconstruction with allogeneous cancellous graft with intramedullary nail was technically challenging because of small medullary canal of the tibia, which is only 1.5mm diameter at isthmus. In literature, documented intramedullary fixation was done with Titanium Elastic nails, Enders Nails^{7, 15}. Use of external frames such as taylor spatial frame, JESS, Ilizarov are reserved usually for older children^{16, 17}. In the present case due to non availability of TENS and Enders of diameter of 1.5mm, a K-wire is used as an intramedullary device to provide stability and alignment in this child. Excision and grafting with vascular fibular grafts or cortical fibular strut grafts are recommended in literature^{18, 19}. Vascularised fibular grafts are technically demanding and autologous cortical strut grafts in a child less than 3 years is practically not feasible. Hence, we have tried allogeneous cancellous strut graft from the parent after ensuing major compatibility as a grafting choice coupled with intramedullary k-wire fixation in treating a pseudarthrosis of tibia in a child less than 3 year old. Attention to internal fixation and fibular continuity are crucial for maintaining alignment and consequently union¹. Hence, after resection of fibrous tissue around fibular pseudarthrosis and excision of periosteum, fibula was fixed with

1 mm k-wire to act as an internal splint and maintain fibular continuity. Toward these goals, immediate contact of bone ends with compression and ample bone graft and biological enhancers are likely to achieve union most frequently. Although similar principles were followed in this case, it resulted in non union.

4. Conclusion:

Pseudoarthrosis is both a biological and mechanical issue. Mechanically although stabilised, biological pathology predominated in this case and resulted in failure. In conclusion, there was no predictor identified for nonunion in this study. Hopefully, in the future, combined surgical and medical treatments that effectively modulate or block the biochemical pathways responsible for congenital pseudoarthrosis will downgrade its recalcitrant status.

5. References :

- [1] Johnston C.E, Birch JG; A tale of two tibias: a review of treatment options for congenital pseudarthrosis of the tibia; J Child Orthop (2008) 2:133-149.
- [2] Hsu LCS, O'brein A.C.M.C, J.P and Hodgson; Valgus deformity of ankle in children with fibular pseudarthrosis; JBJS; 54-A;585-594, Apr 1972.
- [3] Abumunaser LA, Alsayyad MJ; Congenital Pseudarthrosis of the Tibia with Complex Deformity and Multiple Previous Surgeries Treated by Taylor Spatial Frame at Age of 16 Years; JKAU: Med. Sci., Vol. 17 No. 1, pp: 67-78; 2010.
- [4] Aegerter EE; The possible relationship of neurofibromatosis, congenital pseudarthrosis and fibrous dysplasia. J Bone Joint Surg Am 32:618-626.
- [5] Leskelä HV, Kuorilehto T, Risteli J, Koivunen J, Nissinen M, Peltonen S, Kinnunen P, Messiaen L, Lehenkari P, Peltonen J; Congenital pseudarthrosis of neurofibromatosis type 1: Impaired osteoblast differentiation and function and altered NF1 gene expression Bone 44 (2009) 243-250.
- [6] Lehman WB, Atar D, Feldman DS, Gordon JC, Grant AD. Congenital pseudoarthrosis of the tibia. J Pediatr Orthop B. 2000; 9:103-7.
- [7] Kim HW, Weinstein SL. Intramedullary fixation and bone grafting for congenital pseudarthrosis of the tibia. Clin Orthop Relat Res. 2002; (405):250-7.
- [8] Young F, Sinicorpi S, Lee FS, Vitale MG, Roye Jr DP, Choi IH; Treatment of Congenital Pseudarthrosis of the Tibia with Recombinant Human Bone Morphogenetic Protein-7 (rhBMP-7) : A report of 5 cases; J Bone Joint Surg Am; Vol 88-A; No3; Mar 2006.
- [9] Briner J, Yunis E; Ultrastructure of congenital pseudarthrosis of the tibia. Arch Pathol 95:97-99.
- [10] Cui G, Lei W, Li J; Histopathology of congenital pseudarthrosis of the tibia. Zhonghua Yi Xue Za Zhi 82:487-491.
- [11] Wientroub S, Grill F. Congenital pseudarthrosis of the tibia: part 1. European Pediatric Orthopaedic Society multicenter study of congenital pseudoarthrosis. J Pediatr Orthop B 2000; 9:1-2.
- [12] J Charnley; Congenital pseudarthrosis of tibia treated by intramedullary nail. J Bone Joint Surg Am 38:283-290.
- [13] Baker JK, Cain TE, Tullos HS; Intramedullary fixation for congenital pseudoarthrosis tibia; J Bone Joint Surg Am; 74-A;2;Feb 1992.

- [14] Joseph B, Mathew G. Management of congenital pseudarthrosis of the tibia by excision of the pseudarthrosis, onlay grafting, and intramedullary nailing. *J Pediatr Orthop B* 2000;9:16-23.
- [15] Joseph B, Somaraju VV, Shetty SK (2003) Management of congenital pseudarthrosis of the tibia under age 3 years of age: effect of early surgery on union of the pseudarthrosis and growth of the limb. *J Pediatr Orthop* 23:740-746.
- [16] Plawewski S, Carpentier E, Lascombes P, Prevot J, Robb JE. Treatment of congenital pseudarthrosis of the tibia by the Ilizarov method. *J Pediatr Orthop*. 1990;10(6):786-90.
- [17] Fabry G, Lammens J, Van Melkebeek J, Stuyck J. Treatment of congenital pseudarthrosis with the Ilizarov technique. *J Pediatr Orthop*. 1988;8(1):67-70.
- [17] Fabry G, Lammens J, Van Melkebeek J, Stuyck J. Treatment of congenital pseudarthrosis with the Ilizarov technique. *J Pediatr Orthop*. 1988;8(1):67-70.
- [18] Weiland AJ, Weiss AP, Moore JR, Tolo VT. Vascularized fibular grafts in the treatment of congenital pseudarthrosis of the tibia. *J Bone Joint Surg Am*. 1990;72(5):654-62.
- [19] Pho RW, Levack B, Satku K, Patradul A. Free vascularised fibular graft in the treatment of congenital pseudarthrosis of the tibia. *J Bone Joint Surg Br*. 1985;67(1):64-70.