

Contents lists available at BioMedSciDirect Publications

## International Journal of Biological & Medical Research

Journal homepage: [www.biomedscidirect.com](http://www.biomedscidirect.com)



### Case Report

# Laparoscopic cholecystectomy in a patient with ventriculoperitoneal shunt operated cerebral artery aneurysm.

<sup>a</sup>Pradnya Jagtap, <sup>b</sup>Shirish Chavan, <sup>c</sup>Sandhya Gujar, <sup>d</sup>Dipakkumar Chavan

<sup>a</sup>Assistant Professor, Dept. of Anaesthesiology, ESIPGIMS Andheri, Mumbai-93.

<sup>b</sup>Associate Professor, Dept. of Anaesthesiology ESIPGIMS Andheri, Mumbai-93

<sup>c</sup>Professor & HOD, Dept. of Anaesthesiology ESIPGIMS Andheri, Mumbai-93

<sup>d</sup>Junior Resident, Dept. of Anaesthesiology ESIPGIMS Andheri, Mumbai-93

#### ARTICLE INFO

##### Keywords:

*laparoscopy*

*Ventriculoperitoneal shunt*

*Cerebral aneurysm*

#### ABSTRACT

We are describing here elective laparoscopic cholecystectomy with presence of ventriculoperitoneal shunt. Patient had H/O cerebral artery aneurysm, H/O hydrocephalous and H/O placement of programmable type 2 stuart ventriculoperitoneal shunt. He was posted for laparoscopic cholecystectomy. Although ventriculoperitoneal shunt is not formally considered a contraindication for laparoscopic surgery, sometimes shunt failure is also reported which causes high intracranial pressure. Laparoscopic surgery has become preferred method in many operations because it is minimally invasive method with less postoperative pain and post-operative complications (reduced risk of secondary peritoneal adhesions), better recovery, shorter hospital stay and reduced cost of treatment. In this patient the baseline function of shunt was normal. As the shunt was pressure regulated and modern time, there was minimal risk of backflow of CO<sub>2</sub> through distal catheter upwards. Throughout surgery, intra-abdominal pressure was maintained up to 10 mm of Hg. Non-invasive methods of monitoring for EEG, BIS and intracranial pressure were used. The patient was successfully managed for laparoscopic cholecystectomy. In postoperative patient was monitored for vital parameters and intracranial tension.

© Copyright 2010 BioMedSciDirect Publications IJBMR -ISSN: 0976:6685. All rights reserved.

#### Introduction

With the advent in laparoscopic surgeries, different types of patients with co-morbidities are getting operated under laparoscopic methods. Initially laparoscopy was considered contraindication for neurosurgery operated patients because there were high chances of postoperative shunt failure, because of occlusion of shunt by soft tissue, chances of venous air embolism, increased intracranial pressure in intraoperative period.[1,2] With advanced ventriculoperitoneal shunt quality and nonreturnable valve, chances of complication during laparoscopic surgery has become minimal.

Precautions taken during surgery, proper monitoring of patient during anaesthesia and postoperative period patient with ventriculoperitoneal shunt can be successfully managed for laparoscopic surgery without exteriorization or changing ventriculoperitoneal shunt during surgery.<sup>[3,4]</sup>

56 years old man was posted for laparoscopic cholecystectomy with multiple gall stones. Patient had history of operated for cerebral artery aneurysm. Patient had chronic headache, CT and subsequent MRI was done which showed subdural hygroma along fronto-parietal convexity. There was a well-defined saccular aneurysm of about 4 mm in right distal A1 segment of anterior cerebral artery.

Permanent craniotomy was done with decompression and clipping of anterior cerebral artery. After 2 months, patient developed increased intracranial pressure with hydrocephalous. MRI brain with angiogram and venogram report showed craniotomy defect in right frontal bone, aneurysmal clip in right anterior cerebral artery territory, moderate communicating hydrocephalous, no venous sinus thrombosis, no vascular narrowing. Right parietal burr hole was done and communicating programmable type 2 strata ventriculoperitoneal shunt was placed. There was H/O convulsions after surgery which did not require any specific treatment. Coincidentally patient had multiple gall stones and was decided to operate for cholecystectomy laparoscopically for obvious advantages of laparoscopic surgery (less postoperative complication, better skin healing, lesser hospital stay and cost effective).

\* Corresponding Author : **Dr Pradnya Jagtap**

Assistant Professor,

Dept. of Anaesthesiology,

ESIPGIMS,

Andheri Mumbai-93

Email : [mukta2003@in.com](mailto:mukta2003@in.com)

Mobile no. +919819583589

©Copyright 2010 BioMedSciDirect Publications. All rights reserved.

It was a controversial point whether patient should go for open cholecystectomy as patient has ventriculoperitoneal shunt in situ. There are very few references of ventriculoperitoneal shunt and laparoscopic surgery. After careful neurological evaluation with neurological reference for evidence of raised intracranial tension, and functioning of ventriculoperitoneal shunt.

In ophthalmic examination, fundoscopy was normal. All other routine investigations were normal. High risk consent was taken (ASA grade 3). Patient was premedicated with potent opioid buprenorphine 0.2 mg/kg body IV and inj. Glycopyrrolate and inj. Ondansetron. All monitors were attached including BIS monitoring to know depth of anaesthesia and sedation intraoperatively.

Goal was to avoid increase in intracranial pressure, hypoxia, hypercapnia and volatile anaesthetic induced increase in cerebral blood flow.

Patient was induced with inj. Thiopentone sodium 5 mg/kg and intubation was facilitated with nondepolarising neuromuscular blocker Inj. Vecuronium. Lignocaine 100 mg IV was given to attenuate sympathetic response associated with endotracheal intubation.

Maintenance of anaesthesia was with oxygen, nitrous oxide and volatile anaesthetic agent Sevoflurane with vecuronium with controlled ventilation. Hypertension in intraoperative period was treated with nitroglycerine IV infusion titrated to blood pressure measurement.

BIS index was maintained around 60 to prevent intraoperative awareness and to minimise post-operative sedation. Inhalational sevoflurane was titrated according to MAC value and BIS index. ETCO<sub>2</sub> was used to monitor ventilation status and to diagnose unexpected venous air embolism. ETCO<sub>2</sub> was maintained between 25 to 35 mm of Hg. Pulse, ECG and SAO<sub>2</sub> oxygen saturation. ETCO<sub>2</sub> remained within normal limits throughout procedure.

Patient was placed in head high position. Intra-abdominal pressure was low (below 10 mm of Hg) throughout the procedure.[5] During insertion of trocar and cannula increase in intraabdominal pressure and concomitant rise in ICP were avoided by additional bolus of inj. Thiopentone sodium. After insertion of laparoscope, ventriculoperitoneal shunt was traced and free drainage of cerebrospinal fluid was insured.

At the end of surgery, ventriculoperitoneal shunt was again observed. Patient was extubated after slow reversal with inj. Neostigmine and inj. Glycopyrrolate taking care to avoid increase in blood pressure and tachycardia. Patient recovery was uneventful. Patient was conscious, oriented, responding to verbal commands and maintaining normal airway.

Postoperative patient was monitored for 12 hours and no untoward event occurred during post-operative period. Patient was discharged after days.

## Discussion

Patient with ventriculoperitoneal shunt when come with other surgical lesions require consideration of neurophysiology and neurological monitoring. Intra cranial pressure was maintained within normal limits.

Factors affecting intra cranial pressure are as follows

1. Cerebral blood flow (CBF)
2. Cerebral metabolic rate of O<sub>2</sub> (CMRO<sub>2</sub>)
3. Blood pressure (BP)
4. ETCO<sub>2</sub> or hypoxia, hypercapnia

During surgery patient was monitored with EEG, SSEP, MEP, brain stem auditory evoked potential for early detection of neurological insult.

This patient presents with additional risk of

1. Hypercapnia because of CO<sub>2</sub> insufflation,
2. Hypertension because of abdominal distension,
3. Raised intracranial tension as a reflection of increase intra-abdominal pressure so there is congestion of thoracic vessels and resultant back pressure on cerebral vessels and impaired venous drainage from thoracic vessels.
4. Peritoneal adhesions decreasing accessibility
5. Shunt dysfunction
6. Less likely retrograde CO<sub>2</sub> diffusion through distal end of ventriculoperitoneal shunt

In a patient with hydrocephalous with adequate functioning of cerebrospinal fluid shunt has normal baseline intracranial pressure. If pressure is above threshold (preset) level, shunt opens and allows free drainage of cerebrospinal fluid preventing increase in intra cranial pressure.

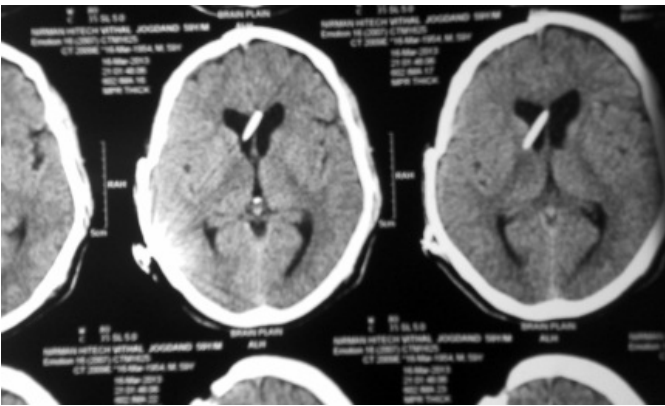
Precautions should be taken during laparoscopic surgery includes

1. To check free drainage of cerebrospinal fluid peri-operatively.
2. To maintain low pressure for pneumoperitoneum upto 10 mm of Hg.
3. To limit duration of pneumoperitoneum (surgery time was 50 minutes) other methods which are discussed to manage patient with ventriculoperitoneal shunt are temporary exterioration of catheter.

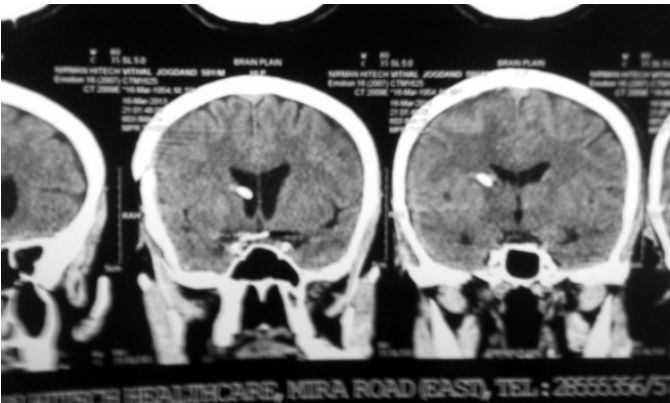4. To clamp ventriculo peritoneal shunt catheter to preserve shunt function.

Now, exteriorisation of catheter and clamping of ventriculoperitoneal shunt catheter are no longer recommended. Transcranial Doppler can be used as a non-invasive method to monitor any small increase in intra cranial pressure associated with pneumoperitoneum.[1,5]

#### MRI Brain showing ventriculoperitoneal shunt.



#### MRI Brain showing ventriculoperitoneal shunt.



#### Conclusion

In our patient laparoscopic cholecystectomy was performed successfully with careful monitoring of intracranial pressure. In postoperative period, patient was again monitored for shunt function and MRI studies which showed normal functioning. With newer versions of ventriculoperitoneal shunt with non-returnable valve, such surgeries can be carried out with less morbidity and mortality if performed with utmost care and monitoring.

#### References

- [1] Uzzo RG, Bilsky M, Mininberg DT, Poppas DP. Laparoscopic surgery in children with ventriculoperitoneal shunts: effect of pneumoperitoneum on intracranial pressure: preliminary experience. *Urology* 1997; 49: 753-7.
- [2] Moncure M, Salem R, Moncure K, et al. Central nervous system metabolic and physiologic effects of laparoscopy. *Am Surg* 1999; 65: 168-72, Medline Web of Science

- [3] Chet W Hammill, MD, Timothy Au, MS4, and Linda L Wong, MD. Laparoscopic Cholecystectomy in a Patient with a Ventriculoperitoneal Shunt. *Hawaii Med J*. 2010 April; 69(4): 103-104
- [4] O. Damrah, P. Naik, G. Fusai, D. Sharma Is laparoscopic cholecystectomy safe for acute cholecystitis in the presence of ventriculo-peritoneal shunt? *Int J Surg Case Rep*. 2011; 2(6): 157-158.
- [5] J. Ravaoherisoa, P. Meyer, R. Afriat, Y. Meyer, E. Sauvanet, A. Tricot et al. Laparoscopic surgery in a patient with ventriculoperitoneal shunt: monitoring of shunt function with transcranial Doppler. *BJA* 2004, 92, 3, 434-437.