



Contents lists available at BioMedSciDirect Publications

## International Journal of Biological & Medical Research

Journal homepage: [www.biomedscidirect.com](http://www.biomedscidirect.com)



### Case Report

## Chromoblastomycosis

Muktamani Gurumayum<sup>a</sup>, Rajendra Okade<sup>b</sup>, Vidyavathi K<sup>c</sup>, Prakruthi K.N<sup>d</sup>, Trupthi Gowda<sup>e</sup>.

<sup>a</sup>Post graduate, Department of Dermatology, Venereology & Leprosy, Sri Devaraj Urs Medical College, Kolar, Karnataka

<sup>b</sup>Prof and HOD, Department of Dermatology, Venereology & Leprosy, Sri Devaraj Urs Medical College, Kolar, Karnataka

<sup>c</sup>Associate professor, Department of Pathology, Sri Devaraj Urs Medical College, Kolar, Karnataka

<sup>d</sup>Post graduate, Department of Dermatology, Venereology & Leprosy, Sri Devaraj Urs Medical College, Kolar, Karnataka

<sup>e</sup>Post graduate, Department of Microbiology, Sri Devaraj Urs Medical College, Kolar, Karnataka

#### ARTICLE INFO

##### Keywords:

Chromoblastomycosis

Sclerotic bodies

Non-healing plaque

#### ABSTRACT

Chromoblastomycosis is a localized chronic mycosis of skin and subcutaneous tissues. It is characterized by verrucous, ulcerated and crusted lesions which may be nearly flat but may be raised 1 to 3 centimeters. Lesions usually are localized to the lower leg but may occur on other skin surfaces at the site of cutaneous injuries. Here, we report a case of non-healing ulcerated plaque after a stick injury in a 65 year old male patient. KOH mount and biopsy showed sclerotic bodies suggestive of Chromoblastomycosis.

© Copyright 2010 BioMedSciDirect Publications IJBMR -ISSN: 0976:6685. All rights reserved.

### 1. Introduction

Chromoblastomycosis is a non-contagious, chronic, localized fungal infection of the cutaneous and the sub-cutaneous tissues, which is caused by several species of phaeoid (*ie. Dematiaceous*) fungi. Conant (1937) was the first to point out that the fungus, *Phialophoraverrucosa*, one of the agents of Chromoblastomycosis, was identical to a fungus which caused "blueing" of wood. They are saprophytes which are found in soil and plants. Chromoblastomycosis is usually known to occur following trauma with wood splinters and it usually occurs on the hands, feet and legs. The actual prevalence and the incidence of Chromoblastomycosis are unknown because of its sporadic case reporting.

#### CASE REPORT

A 65 year old male, who is a farmer by occupation presented to the OPD with non-healing lesion present on inner side of the right lower leg near the medial malleolus of 6 months duration. He gave history of stick injury to the same area 6 months back, after which he noticed an ulcer which was small initially, not associated with pain or discharge and within a period of time progressed to the present size. There was no regional lymphadenopathy.

He didn't give any history of cough, weight loss in the past or any similar lesion anywhere in the body. Systemic examination and routine laboratory work up were essentially normal.

Cutaneous examination revealed a well-defined ulcerated plaque 6x5 cm with central area covered with yellow colored crust and periphery studded with nodules surrounded by erythema and edema. Scales were present at the periphery which were large and adherent (Fig1).

X-ray examination of right foot did not reveal any bone involvement.

D/D of Cutaneous TB, Deep fungal infection, Premalignant and Malignant lesion were considered.

40% Potassium hydroxide preparation showed multiple sclerotic bodies, brown in color (Fig3).

Histopathology from the nodule showed granulomas consisting of histiocytes, lymphocytes, plasma cell, eosinophils and multinucleated giant cells. Focal areas within the granuloma showed collection of round, brown-coloured sclerotic bodies with septa (Fig4).

The lactophenol cotton blue preparation from the culture material showed the presence of septate hyphae with acropetal conidia arising in long branched chains suggestive of *Cladophialophoracarrionii* (Fig5). Culture on Sabouraud dextrose agar with chloramphenicol (50µg) and actidione (50µg) yielded growth which was olive-green colour with cottony texture and black pigment on the reverse when kept at 25°C for 2 weeks (Fig6). Patient was treated with terbinafine 250mg twice a day for a month and showed marked improvement (Fig2).

\* Corresponding Author : Dr. MUKTAMANI GURUMAYUM

Final year post-graduate

Dept of Dermatology

Sri Devaraj Urs Medical College

Tamaka, Kolar-563101, Karnataka, India

Email-dolly123sharma@yahoo.com

Mobile no-9741872702

©Copyright 2010 BioMedSciDirect Publications. All rights reserved.

4105

# CONCLUSION:

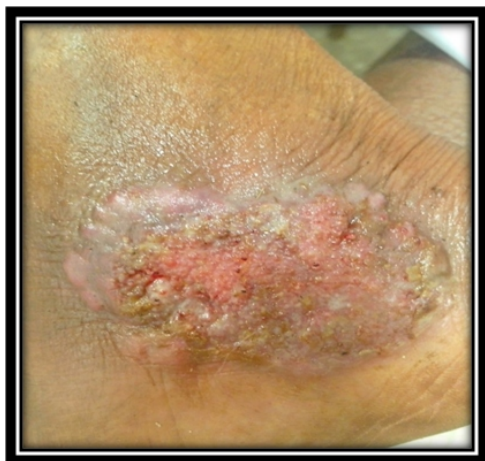

Fig 1: Patient at the time of presentation

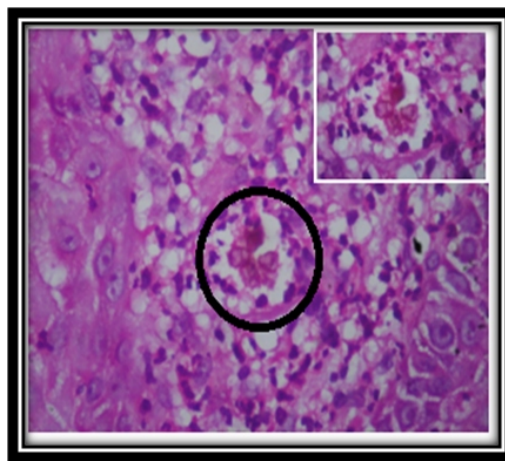


Fig 4: Granuloma with brown-colored sclerotic bodies

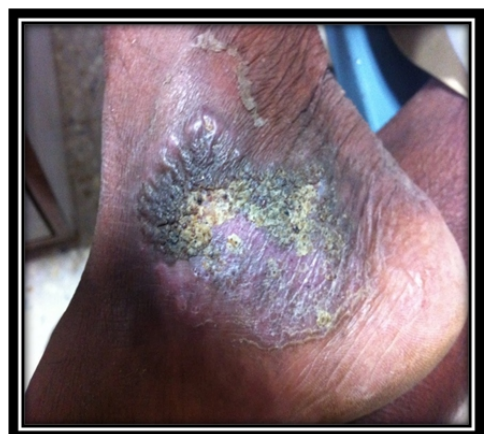

Fig 2: Marked improvement after treatment.

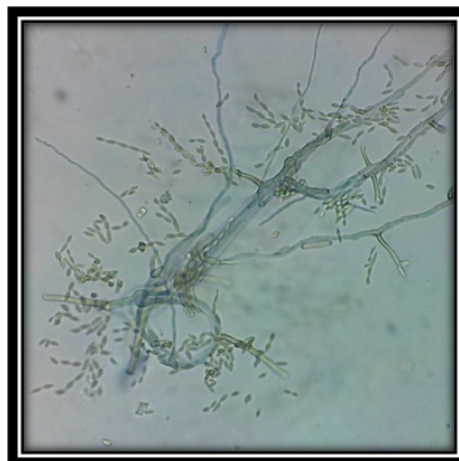


Fig 5: Lactophenolcotton blue preparation color-septate hyphae with acropetal conidia

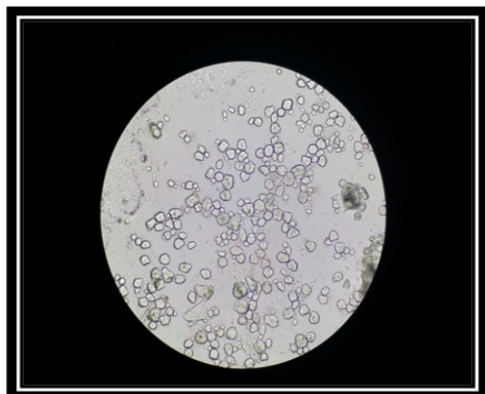


Fig 3. Sclerotic bodies in KOH mount




Fig 6: SDA showing olive-green with cottony texture and black pigment

## DISCUSSION

Chromoblastomycosis is an uncommon chronic deep fungal infection of the skin. Even though it is regarded as a deep fungal infection, it usually localizes to the skin without systemic involvement. Thus, it is the most superficial type of all deep fungal infections.<sup>1</sup> Causative agent belongs to a small group of dematiaceous (pigmented) fungi. At least five species of fungi have been recognized to cause chromoblastomycosis: *Cladosporium carrionii*, *Fonsecaea compacta*, *Fonsecaea pedrosoi*, *Phialophora verrucosa* and *Rhinocladia aquaspersa*.<sup>2</sup> These fungi can be found in vegetation, decaying wood or soil.

Chromoblastomycosis usually presents as slow growing solitary lesion on the extremity. Nodular and tumorous lesions are the most common forms, followed by warty and cicatricial lesions.

The plaque type as in our patient is the least common presentation. Lesions are often pruritic but non-tender.<sup>3</sup> There is usually no systemic symptoms. The disease tends to be chronic and progressive up to many years.

Chromoblastomycosis must be differentiated from blastomycosis, cutaneous tuberculosis, leishmaniasis, malignancy etc. Mycological and histopathological evidence are essential in confirming the diagnosis. The most rapid diagnostic technique is the examination of skin scrapings or biopsy specimen by direct KOH preparation for the presence of muriform/sclerotic bodies.<sup>4</sup> Superficial crusts from the lesions may show the septate, dematiaceous hyphae. Late complications include local destruction, secondary bacterial infection, lymphoedema and development of squamous cell carcinoma.<sup>5</sup>

## TREATMENT :

Triazole derivatives (especially itraconazole) and terbinafine are more effective in treating *Fonsecaea pedrosoi* and *Cladosporium carrionii*. Itraconazole is given at a dose of 200 mg or 400 mg daily for 1 month.<sup>6</sup>

The dose of terbinafine ranged from 250 mg to 500 mg daily for 21 days.<sup>7</sup> The efficacy of these newer anti-fungal agents are based on case reports and open labeled trials. The optimal dose and duration of treatment is still remains to be defined.

Physical modalities such as local thermotherapy, cryotherapy, electrosurgery and radiation have the advantages of relative short duration of therapy and less-expensive.<sup>8</sup> Their efficacies are largely anecdotal.

## CONCLUSION:

Our case was unique because of the presentation as non-healing ulcerated plaque. Although Chromoblastomycosis is very rare, our case demonstrates the need for the consideration of Chromoblastomycosis in differential diagnosis of non-healing plaque.

## Sex distribution :

- [1] Hay RJ. Therapeutic potential of terbinafine in subcutaneous and systemic mycosis. *Br J Dermatol* 1999;141:32.
- [2] Schell WA. Agents of Chromoblastomycosis and Sporotrichosis, Chapter 17. In: Topley and Wilson Microbiology and Microbial Infections, Vol 4. Medical Mycology, 9th edition. Arnold, London. 1998, 220-225.
- [3] Sharma NL, Sharma RC, Grover PS, Gupta ML, Sharma AK, Mahajan VK. Chromoblastomycosis in India. *Int J Dermatol* 1999;38:864-51.
- [4] Mohanty L, Mohanty P, Padhi T. A verrucous growth on the leg. *Indian J Dermatol Venereal Leprol* 1999;72: 399-400.
- [5] Rajendra C, Ramesh V, Misra. Chromoblastomycosis in India. *Int J Dermatol* 1997;36: 29-33.
- [6] Serigny GM, Ramos-Caro FA. Treatment of chromoblastomycosis due to *Fonsecaea pedrosoi* with low-dose terbinafine. *Cutis* 2000;66:45-6.
- [7] Sharma NL, Sharma RC, Grover PS. Chromoblastomycosis in India. *Int J dermatol* 1999;38 (11): 846-51.
- [8] Poirriez J, Breuillard F, Francois N. A case of Chromoblastomycosis treated by a combination of cryotherapy, shaving, oral 5-fluorocytosine, and oral amphotericin B. *Am J Trop Med Hyg* 2000;63:61-3