




Contents lists available at BioMedSciDirect Publications

## International Journal of Biological & Medical Research

Journal homepage: [www.biomedscidirect.com](http://www.biomedscidirect.com)

### Case report

## Left ventricular bronchogenic cyst-an incidental finding on autopsy.

<sup>a</sup>Kanika Taneja, <sup>a</sup>Nisha Sharma, <sup>b</sup>Shilpa Garg, <sup>a</sup>Arsh Gupta, <sup>b</sup>Aditi Arora, <sup>b</sup>Sohrab Arora

*Resident*

*Senior resident, Shaheed Hasan Khan Mewati Govt Medical College, Nalhar, Mewat*

*Assistant Professor, Ram Manohar Lohia Institute of medical sciences Vibhuti Khand Gomti nagar Lucknow*

*Senior Resident, Department of Urology, SGPIMS Lucknow*

*Senior Resident, Department of Pathology*

*Senior Resident*

### ARTICLE INFO

#### Keywords:

*Bronchogenic cysts*

*heart*

*Left ventricle*

### ABSTRACT

**Objective:** Bronchogenic cysts are mostly benign, congenital endodermal rests that arise from abnormal budding in the distal tracheobronchial tree. Resulting structures lose the embryological connections with the parent bronchus and may then migrate to different sites. They are located in the mediastinum, neck, lung and rarely heart. Due to the mostly asymptomatic behaviour and the historical confusion regarding histology, an exact prevalence is not known. **Case report:** We describe here a case of left ventricular wall bronchogenic cyst found incidentally on autopsy. **Conclusion:** Despite the rarity of this pathologic entity, bronchogenic cysts should be considered in the differential diagnosis of cystic lesions of heart. Definitive diagnosis rests on histology. Surgery remains the recommended treatment of choice.

© Copyright 2010 BioMedSciDirect Publications IJBMR - ISSN: 0976:6685. All rights reserved.

### Introduction

Bronchogenic cysts are benign lesions of congenital origin derived from the primitive foregut. [1] Most common presentation is in second to fourth decades of life. Many cases are asymptomatic with the lesions incidentally detected when the patient undergoes a test for another reason. Symptoms develop due to increase in size of cyst or due to infection. Pain and cough are the most common symptoms, followed by dyspnoea and fever. However, most common presentation is asymptomatic and incidental discovery. [1]

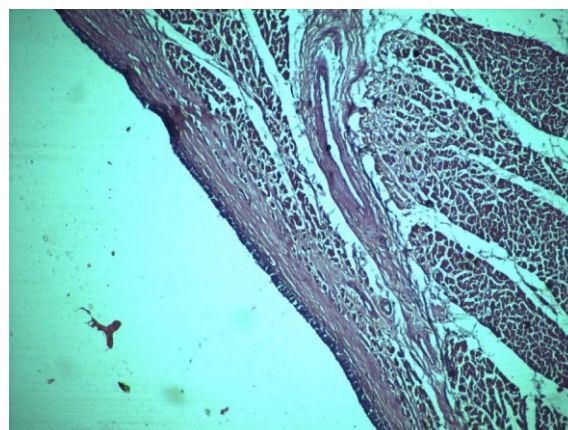
We present an extremely rare case of an incidentally detected left ventricular bronchogenic cyst where patient being unaware of this condition died and presented as an autopsy case.

### Case report

The deceased was a 45-year-old man who presented with left-sided chest pain along with palpitations since half an hour. Previous history of single episode of acute onset chest pain was reported which was relieved spontaneously and patient did not undergo any previous hospitalisation or investigation. There was no history of cardiomyopathy in family, hypertension, smoking, alcoholism, or hormonal disorders. Patient died as he reached the hospital and his body was sent for post-mortem examination. Autopsy findings showed a normal sized heart. On cutting open, thickness of right ventricular wall, left ventricular wall and

interventricular septum were normal. No valvular pathology was seen. Macroscopic examination showed a cystic lesion, 0.8 cm in size, in the left ventricular wall within the myocardium. Wall thickness of cyst was 0.2 cm and it was filled with yellowish-white mucoid material. Microscopic examination showed a cyst lined by ciliated pseudostratified columnar epithelium with interspersed goblet cells and luminal mucin. Wall of the cyst was composed of fibrous connective tissue surrounded by myocardial cells. Ciliated epithelium was highlighted on PAS stain. Hence, diagnosis of bronchogenic cyst was made.

**1. Fig 1: Photomicrograph revealing pseudostratified ciliated columnar epithelium lined cyst in myocardium (H&E X10).**



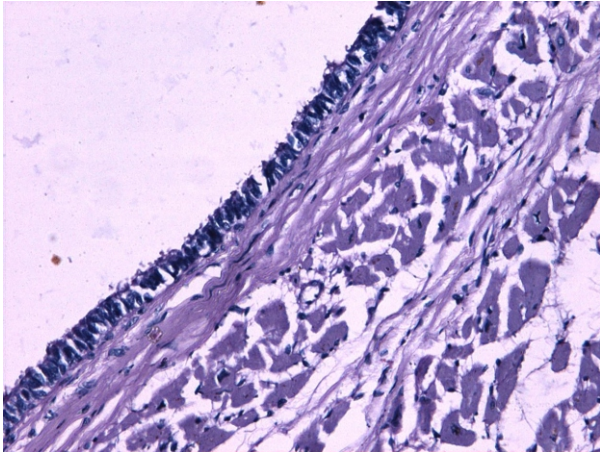
\* Corresponding Author : **Dr. Kanika Taneja**

47 Janak Surgicare Ranjeet Bagh, Passey Road, Patiala

Ph No. 09996699504.

Email address: [drkanikataneja09@gmail.com](mailto:drkanikataneja09@gmail.com)

**Fig 2: Photomicrograph revealing PAS highlighting the columnar epithelium in the myocardium (PASX200).**



## Discussion

Bronchogenic cysts are the most common primary cysts of the mediastinum. However, bronchogenic cysts of the heart are exceedingly rare and usually occur on the epicardial surface or the myocardium with or without projection into one of the cardiac chambers. It is an extremely rare entity. Only a few number of cases have been reported so far. Meyer et al. in 1859 were the first to report a case of a bronchogenic cyst. [2] Bronchogenic cysts represent a localized portion of the tracheobronchial tree that becomes separated from normal airways during the branching process and does not undergo further development. Development occurs between the 26th and the 40th day of intrauterine life, during the most active period of airway development. The timing of abnormal budding determines the eventual location of the cyst: earlier, in the mediastinum; later, within lung tissue. [3]

Although most common locations are the mediastinum and lung, more than 100 case reports with atypical locations of bronchogenic cysts are available in the English literature till date. The frequencies of atypical locations in descending order are: cutaneous (more than 60 cases), retroperitoneal (28 cases), cervical (approximately 18 cases), intra-diaphragmatic (six cases), intrapericardial (six cases), intraspinal (four cases), intracardiac (three cases), and intrapleural cavity (one case). [3]

In our review of world literature, less than 20 cases with cardiac location were found, of which majority reported were located in the right side of the heart, including the interatrial septum, the right ventricular septum, and the right ventricle. [4] In our case, an incidentally detected bronchogenic cyst located within the myocardium of the left ventricle was found on autopsy which is an unusual intracardiac location.

On morphological examination, cyst is frequently unilocular; their fluid content may be clear, or dense and yellow, or hemorrhagic, or mixed with air in case of intrapulmonary location of the cyst. They are lined by columnar ciliated epithelium, and their walls often contain cartilage, bronchial mucous glands and smooth muscle. [1]

In the past, confusion regarding histological criteria has led to misclassification of bronchogenic cysts. The differential diagnosis includes other cysts of foregut origin, cysts of urogenital origin, a cystic teratoma or a bronchopulmonary sequestration. Cysts

originating from the primitive foregut can be classified into bronchogenic, enterogenous and undifferentiated. Oesophageal cysts are lined with ciliated or nonciliated epithelium containing two well-developed layers of smooth muscle without cartilage. Cysts with ciliated epithelium lacking other distinguishing features are called undifferentiated foregut cysts. If seromucous glands or cartilage are described, the diagnosis of anurothelial or mullerian cyst can be ruled out. Acystic teratomas are diagnosed when structures derived from all three germ layers are present. Furthermore, a bronchogenic cyst has to be distinguished from other bronchopulmonary anomalies which may be associated with these especially bronchopulmonary sequestration. The degree of development and location of these structures varies according to the stage of development in embryonic life during which they originated. Since a bronchopulmonary sequestration includes mature lung parenchyma and pleural structures, it can be seen as created later during embryological development. The fluid within the bronchogenic cysts consists of a mixture of water and proteinaceous mucus, with or without components due to previous hemorrhage or infection. [5] Only anatomopathological examination can provide the definite diagnosis.

Diagnosis of such lesions is through radiological work up of patient. Depending on location, X rays, bronchoscopy, oesophagram with barium meal, computed tomography (CT) scan with contrast or magnetic resonance imaging (MRI) can be done for diagnosis. Out of these MRI is the most preferred investigation for localisation of cyst as it provides a clearer image for diagnosis. Also patient should undergo an electrocardiogram (ECG) and echocardiography if cyst is localised in intracardiac location to look for any conduction defects and structural abnormalities, respectively.

Various congenital anomalies of the heart, lung, chest wall and diaphragm have been reported to be associated with bronchogenic cyst. Pericardial defect, patent ductus arteriosus, atrial septal defect, tetralogy of fallot, mitral stenosis, pulmonary sequestration and diaphragmatic hernia have been encountered in association with bronchogenic cyst. [6,7] Also, future malignant degeneration or the presence of a missed malignant tumor raises concerns. Failing to recognize and treat these pathological entities at the moment of diagnosis, can lead to disastrous consequences. For these reasons, early surgical resection of asymptomatic bronchogenic cystic and solid masses is recommended in all good surgical candidates. [5] Several surgical techniques have been described. While drainage of a compressive cyst is used as a palliative procedure in inoperable patients, excision through surgical approaches like thoracotomy and video-assisted thoracoscopic surgery or VATS has emerged as treatment for bronchogenic cyst.

## Conclusion

Intracardiac bronchogenic cysts are extremely rare. [8] Bronchogenic cysts are usually benign, asymptomatic cystic lesions. Most commonly they are encountered in the posterior mediastinum or in an intrapulmonary location. Keeping the embryological development in mind, the presence of bronchogenic cysts at more distant locations can be explained. [5]

Surgical resection of these lesions is recommended in order to alleviate any symptoms, to prevent complications (such as compression, infection, hemorrhage and future malignant transformation) and to establish a definite diagnosis. [5] Only

histology can provide the definite diagnosis. This article describes a rare case of an intracardiac bronchogenic cyst. Although it is an incidental finding in this case, symptoms and clinical manifestations can be variable and bronchogenic cyst should be included in the differential diagnosis of cardiac tumours and cystic lesions of heart.[8]

## References

- [1] Sarper A, Ayten A, Golbasi I, Demircan A, Isin E. Bronchogenic cyst. *Tex Heart Inst J*. 2003;30(2): 105-8.
- [2] Meyer H. Über angeborene blasige missbildungen der lungen, nebst einigen bemerkungen über cyanose als lungenleiden. *Arch Pathol Anat*. 1859;78:p19-32.
- [3] Lee T, Tsai IC, Tsai WL, Jan YJ, Lee CH. Bronchogenic cyst in the left atrium combined with persistent left superior vena cava: the first case in the literature. *AJR Am J Roentgenol*. 2005 Jul;185(1):p116-9.
- [4] Wei X, Omo A, Pan T, Li J, Liu L, Hu M. Left ventricular bronchogenic cyst. *Ann Thorac Surg*. 2006 Apr;81(4): p13-5.
- [5] Govaerts K, Van Eyken P, Verswijvel G, Vander Speeten K. A bronchogenic cyst presenting as a retroperitoneal cystic mass. *Rare Tumours*. 2012 Jan;4(1): e13.p37-44.
- [6] Ahn C, Hosier DM, Vasko JS. Congenital pericardial defect with herniation of the left atrial appendage. *Ann Thorac Surg* 1969;7:p369-84.
- [7] Ribet ME, Copin MC, Gosselin BH. Bronchogenic cysts of the lung. *Ann Thorac Surg* 1996;61:p1636-40.
- [8] Prates PR, Lovato L, Homsi-Neto A, et al. Right ventricular bronchogenic cyst. *Tex Heart Inst J*. 2003;30(1): p71-3.