



Contents lists available at BioMedSciDirect Publications

International Journal of Biological & Medical Research

Journal homepage: www.biomedscidirect.com



Original Article

Outcomes of spine surgery in HIV – seropositive patients : A retrospective study.

*K.Pari ^a, Shahid Yakoob ^b & Saurabh Chaudhary ^c

^aProfessor, Department Of Neurosurgery

^bJunior Resident, Department Of Radiology

^cAssistant professor, Department of Orthopaedics, VMKV Medical college, Salem-636308, India.

ARTICLE INFO

Keywords:

HIV,
Spine surgery,
Outcome of spine surgery,
Post-operative complications.

ABSTRACT

Aim:To analyze the surgical outcome of spine surgery in HIV positive patients
Summary of Background Data:There are very few reports of cases of HIV positive patients undergoing spine surgery for unrelated afflictions. The largest such study is an exclusive study of surgery for tuberculosis of spine. Another notable study reports solely on non-infective conditions of spine undergoing elective surgery. **Methods:** We studied a series of HIV positive patients who underwent spine surgery for various causes including infective, degenerative and metastatic diseases of spine. Surgery was carried out in elective and emergency settings. Post-operative complications and long-term outcome was analyzed. **Results:**Incidence of post-operative complications in HIV positive patients is not unduly high. In patients without significant co-morbidities, outcome was good. In patients with significant other co-morbidities like metastatic disease and serious infection, the outcome was poor. **Conclusions:** Not factoring in the duration and severity of the neuro-spinal disease, outcome depends upon the patient's general health condition and other co-morbidities. Surgical decisions should be taken after evaluating the same.

©Copyright 2010 BioMedSciDirect Publications IJBMR - ISSN: 0976:6685. All rights reserved.

MANUSCRIPT :

Human Immuno-deficiency Virus (HIV) infection is widely common in all parts of the world. Basic science studies have demonstrated impairment of defense mechanism to routine orthopaedic pathogens as well as opportunistic organisms. Clinically, the immune system impairment takes variable amount of time, sometimes 10 years or more. This provides a large window in which an H.I.V. infected patient may need surgical intervention for unrelated causes (1). Definitely, after the patient reaches immune-compromised status, the risk of infections increases manifold. HIV infection and Acquired Immuno- Deficiency Syndrome (AIDS) have a wide variety of related and unrelated neurosurgical manifestations (2-4). Even though numerous studies have examined the peri-operative risks and outcomes in HIV seropositive patients undergoing various surgeries, there is limited evidence-backed knowledge with respect to spine surgeries. This prompted us to review our cases of elective and emergency spine surgeries in HIV sero-positive patients. We undertook to evaluate the morbidity, mortality and natural course of the spinal surgery unrelated to their being HIV sero-positive.

Materials and Methods

This study is a retrospective study in which we studied the medical records of patients operated by the senior author. All HIV sero-positive patients having a spinal disorder requiring surgical intervention were included. A total of 14 patients who were

advised surgery between January 2007 and December 2011 were included. No patient refused surgery. All patients had routine pre-operative check-up consisting of routine blood tests including complete haemogram, hepatic and renal parameters. Chest radiography and serological tests were done. Relevant spinal imaging studies were performed. All cases were operated in accordance with universal guidelines regarding safe surgical practices in HIV sero-positive patients. Duration of surgery, blood loss, difficulties encountered during surgery were noted. All patients had received routine peri-operative antibiotic coverage as required by the procedure.

Post-operative recuperation was evaluated. All patients were followed up every two months for initial six months and suitable regular intervals thereafter till present. Telephonic follow-up was done for the patients not able to come to our OPD for last review.

The outcome of the index problems were decided based upon the magnitude of established outcome endpoints. Also noted were instances of re-infection, pseudoarthrosis, revision of procedure for any reason. Counselling was provided by trained personnel. Case particulars are presented in brief in Table 1.

* Corresponding Author : **K.Pari**

vipa2008@rediffmail.com

Results

There were 8 male and 6 female patients. The age ranged from 25 to 56 years. Thirteen patients underwent elective surgeries and one had an emergency drainage of a cervical perivertebral abscess. There were 9 patients who were receiving anti-retroviral therapy at the time of surgery in accordance with the national programme. The duration of follow-up ranged from 9 months to 2 and ½ years.

There were 5 cases of tuberculosis of spine, all of whom had neurological deficit and one case also had severe kyphosis. All underwent spinal cord decompression with stabilization and fusion. All but one case had significant improvement in neurological symptoms and had a good outcome as per Odom's criteria. One case of TB spine involving 3rd dorsal vertebra had presented with acute onset quadriplegia. Patient came to us after 5 days of quadriplegia was very sick at presentation and had infected bedsores. He underwent costo-transversectomy and cord decompression. Patient showed no improvement in neurological deficit and was discharged from our care after suture removal. Subsequent telephonic enquiry revealed that patient had expired about one month after surgery. Patient had been very sick at home after discharge and further details were not available. In contrast, a 29 year lady on ART who developed extensive tuberculous abscess involving sixth cervical to eleventh dorsal vertebrae with paraparesis recovered almost completely with decompression and fixation (Figure 1).

There were four cases of cervical disc disease with radiculopathy and were managed with anterior cervical discectomy and fusion. All these patients showed excellent recovery in neurodeficit but had mild persistent pain in the neck which resolved gradually over a period of 6 months to 1 year. Outcome in all these cases was graded as good according to Odom's criteria.

There were three cases of lumbar disc disease with radiculopathy and all underwent microlumbar discectomy. All of these patients had good relief of symptoms and had good outcome.

There was one case of extradural perivertebral pyogenic abscess with cord compression and complete quadriplegia (Figure 2). Emergency surgery was performed and abscess was drained followed by antibiotics. Patient improved remarkably over subsequent weeks. Culture from the abscess grew Staph. aureus. He developed wound infection which required debridement and resuturing. Patient had gradual improvement in neuro-deficit. At 3 years of follow-up, he is able to walk without support, even though he continues to have urinary incontinence for which he sought no treatment. His outcome was graded as good.

The last case was a 36 years old female patient who presented with a short history of lower back pain. Patient was ambulant and had features suggestive of neurogenic claudication. Xray of lumbar spine showed collapsed 4th lumbar vertebra. MRI showed destruction of 4th lumbar vertebra with soft tissue mass causing canal compression (Figure 3). Patient was on antiretroviral therapy. Patient underwent decompression and posterior stabilization.

Histopathological examination of the excised mass revealed Non-Hodgkin's Lymphoma. Patient showed improvement in her pain post-operatively and was discharged with advice to undergo chemotherapy. Subsequently patient expired at home 2 months later due to systemic disease.

There were 9 patients taking ART at the time of surgery and 5 who were not. Both groups had mixed etiologies and outcomes were not very different within similar etiological instances. Prolonged antibiotic coverage was not practiced. Anti-TB drugs as per the established regime were prescribed to all patients of tuberculous involvement. No patients had any identifiable postoperative complication which could be attributed to AIDS. There was one case of surgical site infection. No case developed any chest or urinary tract infection in the postoperative period.

Table 1 Master-chart of Cases

Age / sex	HIV	Diagnosis	Neurology presentation	at	Procedure	Neurology post surgery	Outcome	Remarks
56/ m	on ART	D3 TB spine	Complete paraplegia, complete sensory loss, urinary and bowel incontinence, bedsores +		Costo-transversectomy + instrumented stabilization	No clinical improvement	Died at 1 month post surgery, poor	Lost to follow-up, died at home
45/f	On ART	C4C5, C5C6 IVDP, Rt. radiculopathy	Motor 4/5 Sensory Normal		ACDF with iliac graft	Motor 5/5 Neck pain resolving	Improved, Good	
31/ m	On ART	C5C6 IVDP, Rt. Radiculopathy	Triceps 4/5 SJ inverted C6 sensory loss		C5C6 ACDF with iliac graft	Motor 5/5 Neck pain improved, Paresthesia present	Improved, Good	
40/ m	On ART	C1C2 prevertebral + extradural pyogenic abscess, quadriplegia	Complete quadriplegia, absent sensations below neck, Nurick -5/5		Emergency anterior drainage	Quadripareisis Nurick -3/5	Improved, Good	DM, culture: scanty growth of S. aureus
36/ m	Not on ART	C6C7 traumatic IVDP, C7 radiculopathy	Wrist DF 4/5 Elbow ext 4/5 C7 hypesthesia		ACDF with iliac grafting	Motor 4+/5 sensation improved, no pain	Improved, Good	
36/f	Not on ART	C5C6, C6C7 IVDP, Lt C6,C7 radiculopathy	Triceps 4/5, handgrip <100%, TJ-absent, hypesthesia Lt. C6,C7 dermatome		ACDF with iliac graft	Motor 5/5, sensation normal, mild pain persisting	Improved, good	
45/ m	On ART	D8-D10 TB spine, paraparesis	Power 2/5 in lower limbs, hypesthesia below D8 level, urinary incontinence, Nurick - 5/5		ALD, D8 corpectomy with D8D9, D9D10 discectomy, D8D11 anterior stabilization	Power 4/5 Sensation normal Urinary continence achieved Nurick - 2/5	Improved, Good	
25/ m	Not on ART	D11 TB spine, paraparesis	Power 3/5, hypesthesia below inguinal lig Nurick 4/5		ALD, D9D12 Instrumentation	Nurick 1/5	Improved, Good	
29/f	On ART	C6-D11 TB spine, paraparesis	Power 4/5, hypertonion with other UMN signs, hypesthesia below xyphoid, bladder incontinence + Nurick 4/5		ALD, D5-D7 instrumented stabilization with grafting	Nurick - 1/5	Improved, Good	
35/f	On ART	L4L5 IVDP	Lt radiculopathy, EHL weakness 4- /5	L5	L4 laminectomy, L4L5 discectomy	EHL 5/5, no pain	Improved, Excellent	
34/ m	On ART	L4L5 TB spine	Hypesthesia L5,S1 Power 4/5, Continence preserved		L3S1 pedicle screw fixation, L4L5, L5S1 discectomy and intertransverse fusion	Power 5/5 Sensation normal	Improved, Excellent	
34/ m	Not on ART	L2L3 bil radiculopathy	Severe leg pain bilateral		MLD	Pain reduced	Improved, Good	
37/f	Not on ART	L4L5 L5 radiculopathy	Rt. radiculopathy	L5	MLD, bilateral root decompression	No pain, no neurodeficit	Improved, Excellent	
36/f	On ART	L4 lymphoma, bil. radiculopathy	Bilateral radiculopathy, claudication, walking with pain, without support, hypesthesia below L4, power 4+/5		L3L5 laminectomy and posterior stabilization	Pain improved, sensations improved, power 4+/5	Died, Poor	Lost to follow-up, died at home

Figure 1 a: Saggital T2 MR image of patient # 9 showing abscess of the dorsal spine involving almost whole of D6 body and extensive spread under the anterior longitudinal ligament upto C6 superiorly and D11 inferiorly. There is obliteration of anterior epidural space at D6-D7 level.

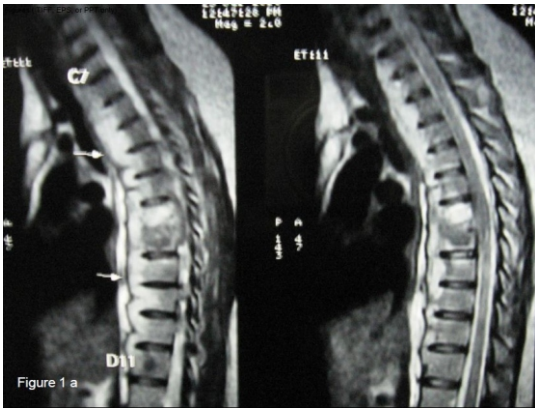

Figure 1 b: Saggital T1, T2 MR images of the same patient at 13months follow-up. Complete resolution of the abscess is seen. Anterior epidural space is also reconstituted. Instrumentation artifacts are seen in bodies of D5, D7.

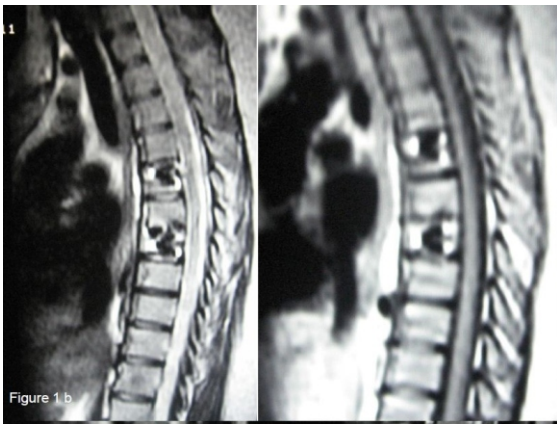


Figure 2 a: saggital T1 MR image of patient #4. Note the hyper-intense pre- and retro-vertebral extent of the abscess causing significant compression of the upper cervical cord

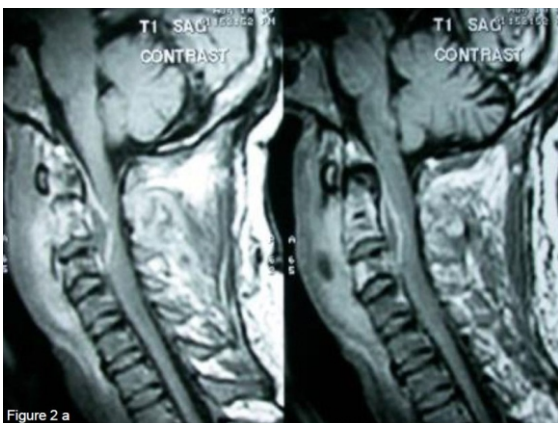


Figure 2 b : T1 axial image at C2-C3 level showing extension of the abscess posterior to the posterior longitudinal ligament and causing significant cord compression.

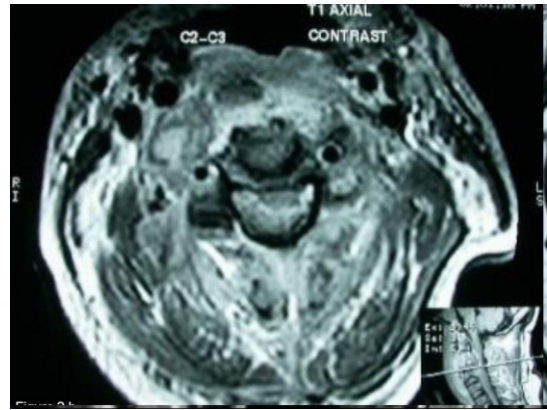
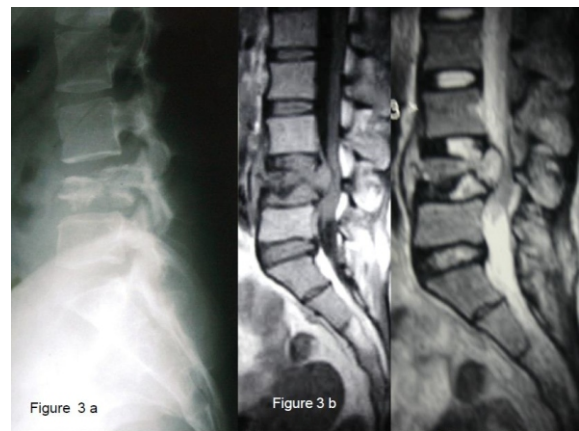


Figure 3 a: X-ray of lumbar spine (lateral view) of patient # 14 showing destruction and fragmentation of L4 vertebral body and resulting kyphus. 3 b: The saggital T1, T2 MR images show severe dural indentation.



Discussion

Spine surgeons practicing in areas with high prevalence of HIV-infected individuals may anticipate that up to 10% of their emergent cases and a highly variable percentage of elective cases will be HIV-positive (1). Despite this, not many studies have reported on the outcome of spine surgery in HIV positive patients. In fact, we could find only one study which examined the issue of elective neurosurgical interventions in HIV positive patients. Young, et al, (5) retrospectively reviewed 10 seropositive patients who underwent spinal procedures for conditions that did not arise as a complication of HIV infection. They had 2 cases of postoperative complications in the form of surgical site infection in one and prolonged unexplained fever in another, but both recovered with medical care. All of their patients improved aftersurgery. They opined that spine surgery can give acceptable outcomes in selected cases. None of their cases, however, included infective conditions of spine. This important subset of patients is probably rising as TB of spine remains a common condition for a spine surgeon. Nontuberculous infections are also more common in immune-compromised patients. In fact, in our study, the largest

subset of patients belonged to tuberculous infection of spine. In Govender's (6) prospective study of patients with spinal TB, the pattern of disease was found to be altered in seropositive patients, with much more extensive spread of the infection along the anterior longitudinal ligament, covering a larger number of vertebrae. One patient in our series (patient number 9 in the table) had such an extensive involvement (C6 – D11) which resolved completely over a period of 13 months with appropriate treatment. Buehrer, et al, (7) studied one-hundred and two patients with hemophilia A, hemophilia B, or acquired antibody to factor VIII who had undergone a total of 169 invasive procedures. They found no significant differences between the wound infection rates of HIV-positive and HIV negative hemophiliacs. They concluded that surgery in HIV-1-infected patients who have not progressed to AIDS does not entail an increased risk of postoperative wound infections.

Greene, et al, (8) reported their study involving thirty patients who had hemophilia and were seropositive for the human immunodeficiency virus. After orthopaedic procedures, one patient developed skin infection at catheter site and five had unexplained fever which subsided with medical care. A more rapid progression to acquired immunodeficiency syndrome was seen in the patients who had a lower CD4 lymphocyte count preoperatively.

They were of the view that preoperative evaluation of the CD4 lymphocyte count and the response to intradermal skin-test antigens in patients who are at risk for infection postoperatively provides additional information concerning immunological competence. With these data, the possible risk of infection in patients who are seropositive for the human immunodeficiency virus can be estimated more accurately.

Hoekman, et al, (9) reported on a prospective study of 214 patients who had elective extensive operations for fractures. They compared the relative frequencies of postoperative infections in the seventeen patients who were seropositive for human immunodeficiency virus and had associated clinical symptoms, in the twenty-six patients who were seropositive and had no associated clinical symptoms, and in the 171 patients who were seronegative. They found that the relative frequency of postoperative infection was significantly higher in patients who were seropositive and had associated clinical symptoms (four of seventeen) than in patients who were seronegative (eight of 171). In all patients who were seropositive and had a postoperative bacterial infection, treatment with antibiotics was effective. The results of this study suggest that people who are seropositive for human immunodeficiency virus and have associated symptoms are at increased risk for postoperative infection. Interestingly, none of the surgeons in their study were aware of the HIV serostatus of their operated patients and no patient received intravenous prophylactic antibiotics.

Heary, et al, (10) studied 19 HIV sero-negative and 13 HIV sero-positive patients with spinal epidural abscesses, vertebral osteomyelitis or both. In both the groups, *Staphylococcus aureus* (72%) and *Mycobacterium tuberculosis* were the common organisms. The clinical presentations in both groups were similar with pain as the most frequent symptom and objective neurologic abnormalities on physical examination in 29 of the 32 patients (91%).

After neurosurgical intervention, 10 HIV positive (76.9%) and 13 HIV negative patients (68.4%) improved neurologically and no patient's condition deteriorated further. They found no

statistically significant difference in the neurologic outcomes between the two groups. The results of this analysis show that the clinical presentations, organisms cultured and neurological outcomes do not differ depending upon a concurrent HIV infection. They further commented that the ultimate neurologic outcome of patients with spinal infections depends on their neurologic status at the time of treatment and not on their HIV status.

Metta, et al, (11) and Sathi, et al, (12) reported one case each of epidural and subdural spinal abscess in HIV positive patients who were treated with appropriate surgical intervention and medical treatment and had good neurological outcome. Kaushik, et al, (13) reported a case of brain abscess in an HIV positive patient who underwent stereotactic aspiration followed by 4- drug anti-TB regime with good recovery.

On the contrary, Paiement, et al, (14) found increased postoperative infection rates in clinically asymptomatic HIV seropositive patients as compared to HIV-seronegative patients. Among 476 patients undergoing orthopaedic trauma surgeries, the surgical postoperative infection rate was 16.7% in seropositive patients and 5.4% in the seronegative group. When open fractures were considered separately, the seropositive group had a 55.6% infection rate compared with 11.3% in the seronegative group. Both these differences were statistically significant. Similarly, seropositive patients also had significantly increased rates of postoperative non-wound infections and complications. They concluded that asymptomatic HIV-seropositive orthopedic trauma patients are at significantly higher risk for postoperative infections than their seronegative counterparts.

Luck, et al, (15) recommended an assessment of the HIV-positive patient's immune status, including the CD4 lymphocyte count, history of opportunistic infection, serum albumin level, the presence of skin anergy, and the state of nutrition and general health before elective surgeries in HIV patients.

Recommendations for surgical interventions in HIV and its subsequent syndrome of immunodeficiency are still evolving. For an asymptomatic HIV patient with history of opportunistic infections and with normal blood cell counts, there appears to be no reason to withhold the surgery. Even for the symptomatic patient, current medical management appears adequate to reduce the risk of early postoperative infection. Decisions regarding elective surgery should be made on a risk-benefit basis. Medical treatment of HIV and tuberculosis together is difficult for many reasons. Combination of the two has been associated with suboptimal serum concentrations of some retroviral drugs and occasionally transient reactivation of TB (16). Also, the burden of these two drug regimens is heavy for the patient and adverse reactions, sometimes requiring stoppage of all drugs, is common (17). These issues become important in patients who present with spinal TB and previously undiagnosed AIDS and in whom, both these therapies may have to be started peri-operatively.

Conclusion

Spine surgery in HIV positive patients has an outcome depending probably upon the general condition of the patient and the immune-competence level of the patient. We feel that the procedures for degenerative and traumatic conditions of the spine in an otherwise asymptomatic HIV infected patient can be undertaken expecting an outcome comparable to that in non- HIV infected patients. Surgeons however should be more cautious in planning elective surgeries on patients affected with serious

infections and neoplastic conditions, taking into consideration their general debilitation. Our results of spine surgery on HIV patients have been encouraging.

Authors note that less number of cases in multiple inhomogenous groups is a drawback of our present study. For the same reason, statistical analysis has not been attempted. But it is sincere belief of the authors that sharing our encouraging results in HIV-seropositive patients operated for various spinal problems would have an impact on the current surgical practice in relation to this patient group which is likely to be sizeable in foreseeable future. Larger multi-centric studies are needed to add to the knowledge on this important subject.

Acknowledgements:

All participants without whom the study would not be a success. There was no external funding sources.

References:

1. Luck J. Orthopedic surgery on the HIV positive patient: complications and outcome. Instructional Course Lecture 1994;43:543-9.
2. Wadia S. Neurological manifestations of the acquired immunodeficiency syndrome (AIDS). Neurosciences 1998; 39-16,
3. Adeloye A. Neurological and neurosurgical manifestations of human immunodeficiency virus (HIV) infection in Africa. East Central African J of Surg Vol. 5, No. 2; 49-54
4. Bono CM. Spectrum of spine infections in patients with HIV: a case report and review of the literature. Clin Orthop Relat Res. 2006 Mar;444:83-91.
5. Young WF, Axelrod P, Jallo J. Elective spinal surgery in asymptomatic HIV-seropositive persons: perioperative complications and outcomes. Spine (Phila Pa 1976). 2005 Jan 15;30(2):256-9.
6. Govender S, Parbhoo AH, Kumar KP, Annamalai K. Anterior spinal decompression in HIV-positive patients with tuberculosis. A prospective study. Bone Joint Surg Br. 2001 Aug;83(6):864-7.
7. Buehrer JL, Weber DJ, Meyer AA, Becherer PR, Rutala WA, Wilson B, Smiley ML, White GC 2nd. Wound infection rates after invasive procedures in HIV-1 seropositive versus HIV-1 seronegative hemophiliacs. Ann Surg. 1990 Apr;211(4):492-8.
8. Greene W, Degnore L, White G. Orthopedic procedures and prognosis in hemophilic patients who are seropositive for human immunodeficiency virus. J Bone Joint Surg Am 1990;72:2-11.
9. Hoekman P, Van DePerre P, Nelissen J, et al. Increased frequency of infection after open reduction of fractures in patients who are seropositive for human immunodeficiency virus. J Bone Joint Surg Am 1991;73:675-9.
10. Heary RF, Hunt CD, Krieger AJ, Vaid C. HIV status does not affect microbiologic spectrum or neurologic outcome in spinal infections. Surg Neurol. 1994 Nov;42(5):417-23.
11. Metta H, Corti M, Redini L, Yampolsky C, Shtirbu R. Spinal epidural abscess due to Mycobacterium tuberculosis in a patient with AIDS: case report and review of the literature. Braz J Infect Dis. 2006 Apr;10(2):146-8.
12. Sathi S, Schwartz M, Cortez S, Rossitch E Jr. Spinal subdural abscess: successful treatment with limited drainage and antibiotics in a patient with AIDS. Surg Neurol. 1994 Nov;42(5):424-7.
13. Kaushik K, Karade S, Kumar S, Kapila K. Tuberculous brain abscess in a patient with HIV infection. Indian J Tuberc. 2007 Oct;54(4):196-8.
14. Paiement GD, Hymes RA, La Douceur MS, et al. Postoperative infections in asymptomatic HIV-seropositive orthopedic trauma patients. J Trauma 1994;37:545-51.
15. Luck JV Jr, Logan LR, Benson DR, Glasser DB. Human Immunodeficiency Virus Infection: Complications and Outcome of Orthopaedic Surgery. J Am Acad Orthop Surg. 1996 Nov;4(6):297-304.
16. API Consensus Expert Committee. API TB Consensus Guidelines 2006: Management of pulmonary tuberculosis, extra-pulmonary tuberculosis and tuberculosis in special situations. J Assoc Physicians India. 2006 Mar;54:219-34.
17. [Tuberculosis in compromised hosts]. Kekkaku. 2003 Nov;78(11):717-22.