

Case Report

ALLOPURINOL INDUCED STEVENS – JOHNSON SYNDROME

¹Dr. Amrith Vijayan*, ²Dr. Lydia B. Peters; ³Arya Rajan

¹Clinical Pharmacy Intern, SUT Royal Hospital, Ulloor, Thiruvananthapuram

²Clinical Pharmacist, SUT Royal Hospital, Ulloor, Thiruvananthapuram

³Doctor of Pharmacy Student, Department of Pharmacy Practice, Sree Krishna College of Pharmacy and Research Centre, Parassala, Thiruvananthapuram, Kerala, India

ARTICLE INFO

Keywords:

Allopurinol,
Stevens - Johnson syndrome,
drug reaction,
pharmacovigilance,
hypersensitivity

ABSTRACT

Stevens-Johnson syndrome is a severe hypersensitivity reaction that typically involves the skin and the mucous membranes, usually occurs as a reaction to a medication or an infection. Most common cause for SJS are drug such as allopurinol, carbamazepine, phenytoin, phenobarbital and cotrimoxazole. 39 year old lady presented with intense erythematous lesions all over the body for past 5 days. The reaction was probably evoked by allopurinol. She was treated with corticosteroids, antimicrobial drugs and oral topical anaesthetics.

© Copyright 2018 BioMedSciDirect Publications IJBMR - ISSN: 0976:6685. All rights reserved.

Introduction:

Modern day drug therapy for the management of various diseased condition has made great stride in the recent past. But, one of the major threat for providing patient care, although rare, is adverse drug reaction. ADR. Stevens-Johnson syndrome (SJS) is one such fatal drug reactions

Stevens-Johnson syndrome is a type IV (subtype C) hypersensitivity reaction that typically involves the skin and the mucous membranes, usually occurs as a reaction to a medication or an infection. (1)

Drugs are most commonly implicated for causing 77-95% of cases (2).

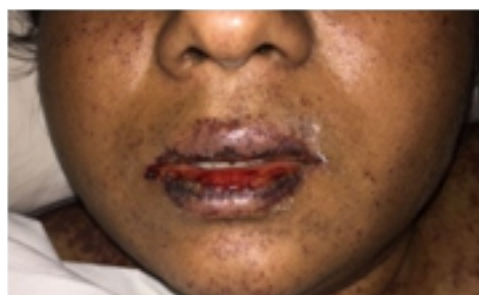Common culprits are allopurinol, anti-infective sulphonamides (especially cotrimoxazole), carbamazepine, phenytoin, phenobarbital and NSAIDs mainly oxim, with increasing risk estimates for allopurinol, making it the leading cause of SJS in Europe and Israel.

The exact pathogenesis of SJS still remains largely unknown. Specific genetic predispositions, which vary among ethnic groups and differ between certain causing drugs, were identified. Certain HLA alleles play an important role in this respect (4).

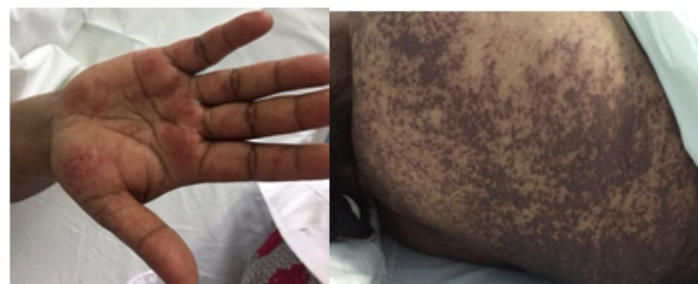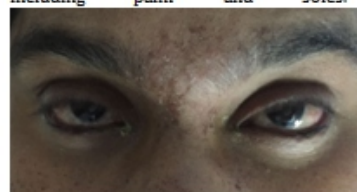
Allopurinol is a xanthine oxidase inhibitors, used for the treatment of Gout. It acts by inhibiting the conversion of hypoxanthine to uric acid and thereby decreases the production of uric acid without disrupting synthesis of vital purines.

Case report

39 year old lady with no prior comorbidities presented with intense erythematous lesions all over the body for past 5 days. Initially rash developed over back of chest which was extremely itchy followed by spreading to rest of the portion of the body,



including palm and soles.



* Corresponding Author : **Dr. Amrith Vijayan**

Clinical Pharmacy Intern, SUT Royal Hospital, Ulloor,

Thiruvananthapuram

Contact No: +918891875637

Email ID: amrithvijayan@writeme.com

She was suffering from Tennis elbow (R) side and cervical spondylosis for the past two months for which she started treatment from 15 days before onset of symptoms (Meloxicam, Allopurinol, Etorocoxib, and Gabapentin)

In-between, she had vertigo for which T. Betahistine 16mg was started. Two days after that, the presenting symptoms started. Initially she took treatment from a nearby hospital. There she was started on Moxifloxacin eye drops and Lidocaine buccal spray and referred here for further management.

Her vitals were stable. Her complete blood picture revealed hemoglobin 12.7g/dl, raised ESR - 27 mm/1st hour & total leucocyte count was 5500 cells/mm³, platelet count was 4,70,000/mm³. CRP was elevated to 15.1.

Based on this our clinical diagnosis was Stevens Johnson Syndrome. Even though she was taking several drug, the most possible culprit is allopurinol. It is proven to produce SJS even after 2 weeks of stopping the drug. Treatment started with IV Steroids (Methylprednisolone), Antibiotic (T. Ciprofloxacin and Moxifloxacin eye drops) and other supportive measures. Eye drops and ointment for local application were also given. Within 24 hours the marked redness of the eyes cleared, the haemorrhagic crusting of the lips were decreased and she was able to take oral feeds. On the 2nd day of admission, 3 blisters appeared on her back broken down. These lesions were not extensive enough to make a diagnosis of Toxic Epidermal Necrolysis. By the application of T bact and Metrogyl, the lesions started healing. Dermatology consultation was given who advised to apply topical Betnovate cream mixed with liquid paraffin on trunk and extremities. Erythematous lesion improved, haemorrhagic crusting of the lips decreased, skin peeled lesion appears dry and no new lesions developed. There was no systemic involvement and renal function remains normal.

The causality assessment performed with Naranjo algorithm revealed the ADR to be Probable (Naranjo score 7). Assessment of causality with the algorithm of drug causality for epidermal necrolysis (ALDEN) [2] showed 'very probable'. Severity-of-illness and prognosis was evaluated by using the SCORTEN criteria. We did not try to test the effects of re-challenge in our patient. Proper counselling was given to patient and relatives.

Conclusion

SJS is a rare and serious systemic cutaneous reaction. Early recognition and discontinuation of the offending drug improves the prognosis of SJS, especially after exposure to drug. Efficient pharmacovigilance is the need so that incidence of adverse drug reactions can be minimised and prevented. Taking proper medical and medication history before prescribing drugs like antibiotics, anticonvulsants, NSAIDs, pyrazoles and anti-rheumatic drugs can reduce this kind of incidence. Reporting of such events should be encouraged

REFERENCES

1. Stevens - Johnson syndrome [Internet]. Practice Essentials, Background, Pathophysiology. 2017 [cited 2018Apr7]. Available from: <https://emedicine.medscape.com/article/1197450-overview>
2. Patel T, Barvaliya M, Sharma D, Tripathi C. A systematic review of the drug-induced Stevens-Johnson syndrome and toxic epidermal necrolysis in Indian population. 2018.
3. Allopurinol Induced Stevens – Johnson Syndrome: A Rare ... [Internet]. [cited 2018]. Available from: <http://keralamedicaljournal.com/2016/03/30/allopurinol-induced-stevens-johnson-syndrome-a-rare-case-report/>

4. Maja Mockenhaupt (2011) The current understanding of Stevens–Johnson syndrome and toxic epidermal necrolysis, Expert Review of Clinical Immunology, 7:6, 803-815, DOI: 10.1586/eci.11.66

5. Paik S, Sen S, Das J, Saha B, Tripathi SK. Allopurinol Induced Stevens – Johnson Syndrome - A Case Report. Journal of Clinical and Diagnostic Research : JCDR. 2015;9(2):WJ01-WJ02. doi:10.7860/JCDR/2015/11786.5558.