

Original Article

Achrochordons as a cutaneous sign of insulin resistance

Nitika Nijhara*, Arvind Krishna, DivyaArora

Department of dermatology, venereology and leprosy, subharti medical college, meerut, uttar pradesh-250005

ARTICLE INFO

Keywords:

Antimicrobial sensitivity
Bacterial isolates
Out Patient Department
Urinary tract infections.

ABSTRACT

Achrochordons, commonly known as skin tags, are common benign connective tissue tumors of the dermis, composed of loose fibrous tissue. It presents as a soft, skin-coloured to slightly hyperpigmented papule. Aims: To study achrochordons as a cutaneous sign of insulin resistance. Methods: A hospital based, cross-sectional prospective study was conducted on 100 patients with clinically diagnosed achrochordons conducted in the Dermatology outpatient department between January 2017 and June 2018 (18 months). Patients having more than or equal to 5 skin tags anywhere on their body were included in the study. Patients <18 years of age, pregnant and lactating women and patients with a known colonic polyposis disease were excluded from the study. A thorough history taking and examination with respect to the onset, site, duration and progression of achrochordons was taken. The homeostatic model assessment (HOMA) was used to quantify insulin resistance (IR) in these patients. A cut-off value of 2.5 or more signified presence of insulin resistance. Results: Most patients (81 out of 100) were seen to have HOMA-IR values equal or more than 2.5. 44.4% of patients with HOMA-IR more than 2.5, had 5-10 achrochordons. The most common age group in patients with HOMA-IR more than 2.5 was 31 to 40 years (39.5%) followed by 41 to 50 years (29.6%) and 18 to 30 years (19.8%). Conclusion: Although there have been plenty of studies from the West reporting skin tags as a cutaneous sign of insulin resistance, there are no large scale Indian studies evaluating Asian patients. The present study was an endeavour in this regard. We may propose that skin tags may be one of the important skin markers of metabolic disorders and may attract physicians and dermatologist for further investigation as it is proved to be not just a cosmetic problem.

© Copyright 2010 BioMedSciDirect Publications IJBMR - ISSN: 0976:6685. All rights reserved.

1. Introduction

Achrochordons, known to lay people as skin tags, are brown or flesh-coloured soft papules attached by a stalk which occurs in 25% of the general population.[1] Achrochordons are usually asymptomatic however a patient may complain of pruritus or discomfort especially when it is snugged by clothing or jewellery or in case of infarction secondary to torsion.[2]

Although benign and of little significance, they have been observed to have a correlation with systemic disorders like diabetes mellitus, obesity, metabolic syndrome, colonic polyposis and acromegaly.[3]

The homeostatic model assessment (HOMA) is a method used to quantify insulin resistance and beta-cell function.

* Corresponding Author :

MATERIALS AND METHODS

A hospital based, cross-sectional prospective study was conducted on 100 patients with clinically diagnosed achrochordons. This study was conducted in the Dermatology outpatient department of Subharti Medical College, Meerut between January 2017 and June 2018 (18 months) after obtaining ethical committee clearance and informed consent from all patients. Patients more than 18 years of age with more than or equal to 5 skin tags anywhere on their body were included in the study. Exclusion criteria were pregnant and lactating women and patients with a known colonic polyposis disease. A thorough history taking with respect to the onset, site, duration and progression of achrochordons, associated dermatoses and detailed personal, past and treatment history was recorded.

Patients were thoroughly examined for the number, type and morphology of skin tags, other cutaneous manifestations and systemic involvement. Laboratory tests like fasting glucose and

basal insulin were performed for each patient. Investigations were sent to the same laboratory throughout the study. HOMA was calculated as :

$$\text{HOMA - IR} = \frac{\text{fasting blood glucose (mg/dl)} \times \text{fasting insulin (mU/ml)}}{405}$$

HOMA-IR values equal or more than 2.5 was used to signify insulin resistance in our study. Individual case records were maintained in the form of case proforma along with photographic evidence. The significance of study parameters was calculated by student's t-test for continuous data. Clinical features were correlated with each other using chi-square test. P value of <0.05 was considered significant.

RESULTS

Of the 100 patients studied, age of the patients varied from 18 to 59 years with an average age of 36.68 ± 10.87 years. Maximum number of patients (43%) belonged to the age group 31-40 years (FIGURE 1). 67% of our study population were females (FIGURE 2). In our study, most patients with achrochordons were housewives (55%) followed by businessmen (23%). Rest of the population included teachers (8%), farmers (7%), students (4%) and salesmen (3%)(FIGURE 3).In majority (75%) patients in our study, neck was noted to be the most common site for achrochordons. Other sites were axilla, face and eyelids in the patients studied (TABLE 1). In our study we noted a high incidence of acanthosisnigricans in patients (69%). 44% patients had 5 to 10 achrochordons (FIGURE 4). In our study, we noted fasting glucose levels more than 100 in 44 patients(TABLE 2). Median value of fasting insulin levels in our study was 18.63(TABLE 3). 81 out of 100 patients were seen to have positive results for HOMA-IR values(TABLE 4). In our study, the most common age group in patients with HOMA-IR more than 2.5 was 31 to 40 years (39.5%). HOMA-IR more than 2.5 in the age group of 31 to 40 years was found to be statistically significant (P value - 0.011) (FIGURE 5). The progression in size of lesion was higher in patients with HOMA-IR more than 2.5 (81.5%) as compared to patients with HOMA-IR less than 2.5 (31.6%) (P value - 0.0001) which was a significant finding (TABLE 5).In our study, most patients with HOMA-IR more than 2.5 had fasting insulin value more than 25 in 58% patients which was statistically significant (FIGURE 6).

FIGURES

FIGURE I : AGE OF PATIENT

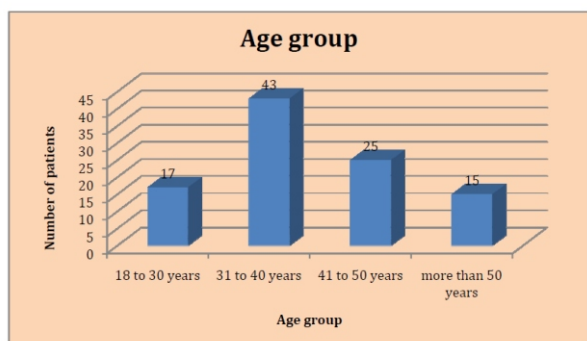


FIGURE II : SEX OF PATIENT

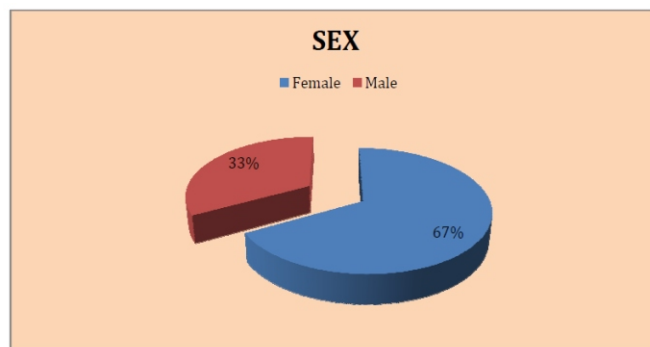


FIGURE III : OCCUPATION OF PATIENT

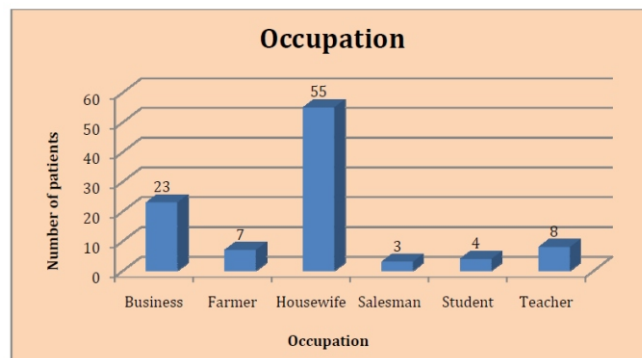


FIGURE IV : NUMBER OF LESIONS

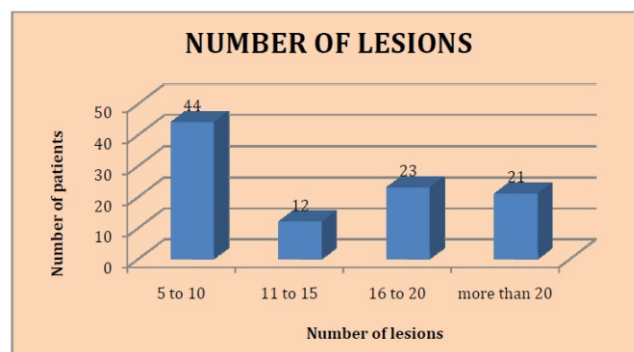


FIGURE IV : AGE GROUP AND HOMA - IR

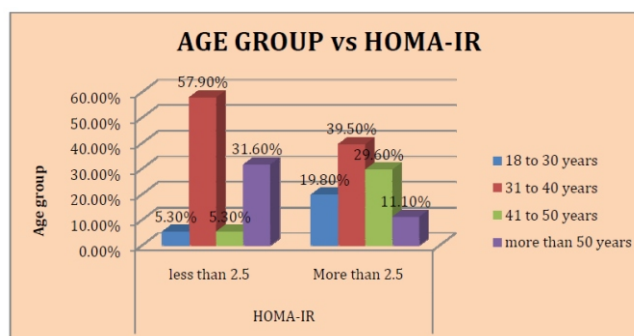


FIGURE VI : FASTING INSULIN AND HOMA - IR

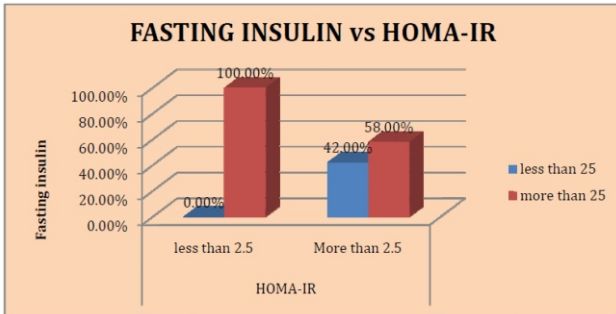


FIGURE VII : Multiple skin tags with underlying acanthosisnigricans over axilla

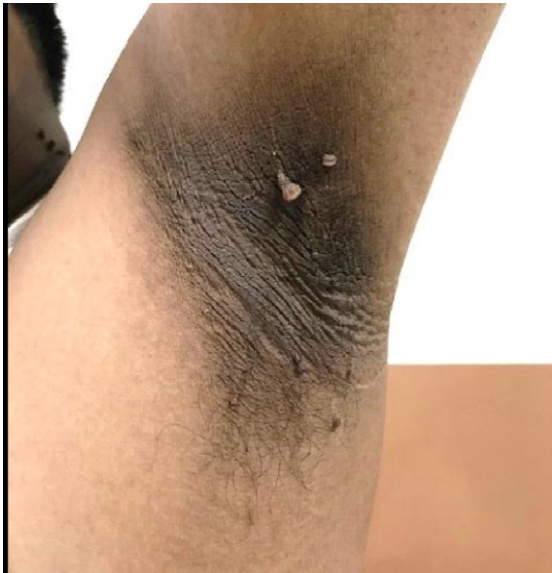

FIGURE VIII : Multiple pedunculated and sessile skin tags of both dark and skin colour present over axilla.

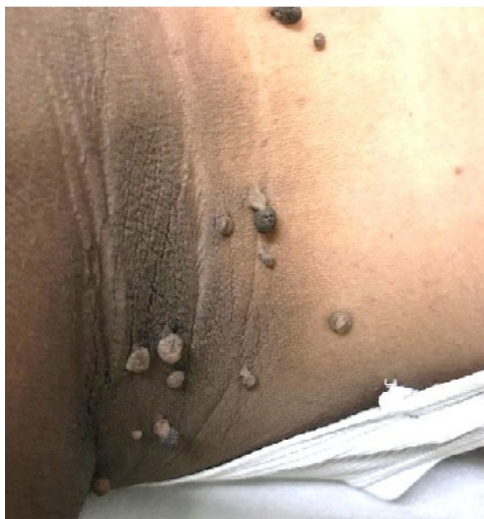

FIGURE IX : Multiple skin tags with acanthosisnigricans present over neck in an obese male.

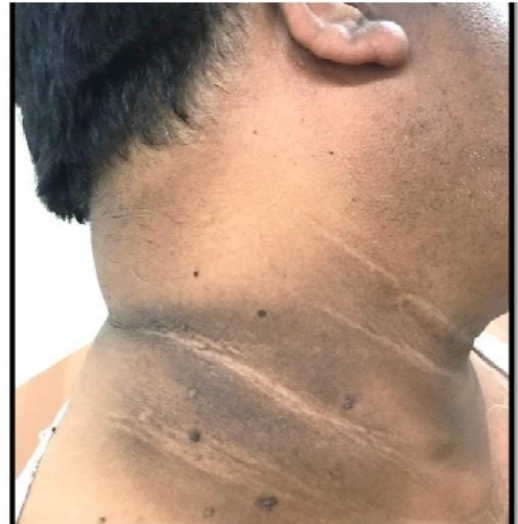

FIGURE X : Skin tags present over upper eyelid in a female

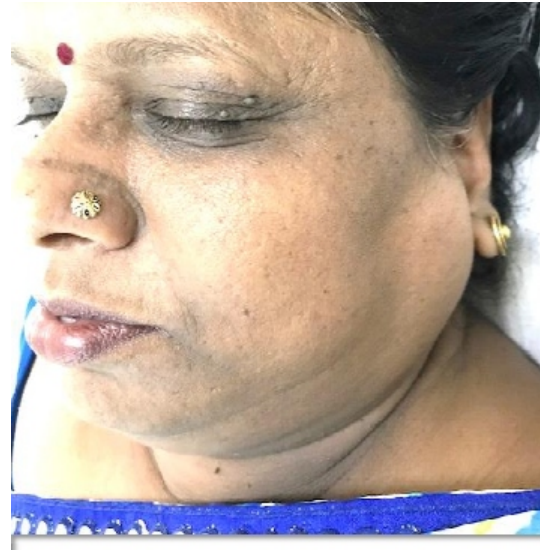

TABLE 1:SITE OF ONSET OF LESIONS

Site Of Onset	Frequency (N)	Percent (%)
Neck	75	75.0
Axilla	21	21.0
Eyelid	2	2.0
Face	2	2.0
Total	100	100.0

DISCUSSION

Achrochordons are soft, small, skin-coloured to dark brown sessile or pedunculated papillomas commonly occurring on the neck, frequently seen on the axilla and eyelids and less often on the trunk and groin.[4]

They appear to be merely of cosmetic concern, but may be associated with a hyperinsulinaemic state. Insulin is well recognized to be a growth-stimulating hormone that can act via the action of insulin-like growth factor-1 receptors to stimulate the development of skin tags.

In the present study, maximum number of patients (43%) belonged to the age group 31-40 years. A study by Srivastava et al [5] noted that majority of their patients i.e., 28.57% of the total 165 patients, belonged to 31-40 years group. The significant positive correlation of skin tag number with age agrees with the literature showing an increasing frequency of skin tags up to the fifth decade. This could be attributed to an extent to the fact that monocyte chemoattractant protein-1; a chemoattractant for mast cells (which are involved in the pathogenesis of skin tags), increases with age.[6]

We noted a high female : male ratio (2.03:1). 67% of our study population were females. Our finding was in accordance with Maluki et al [7] and Bhargava et al [8] who noticed a female preponderance (M:F = 1:2.92 and 1:1.78 respectively). We propose two theories to support the same. One possibility is the higher incidence of skin tags in women or secondly, women seek medical intervention for cosmetic purposes more often than men.

In our study, most patients with achrochordons were housewives (55%) followed by businessmen (23%). Rest of the population included teachers (8%), farmers (7%), students (4%) and salesmen (3%).

In a study by Mustafa et al [9], majority cases were of uncertain jobs (free jobs) representing 36 (60%), whereas professional worker presented 11 patients represented (18.3%), farmers were 8 patients (13, 3%) while clarks were only 5 (8.3%) among them. We infer from the above that, most skin tags are noted in people who have a sedentary lifestyle or are engaging in minimal daily physical activities. Farmers who are engaged in more rigorous physical activity, constituted a small percentage of our study population and this reinforces the above proposed theory.

In majority (75%) patients in our study, neck was noted to be the most common site for achrochordons. Other sites were axilla, face and eyelids in the patients studied. This frequency is in accordance with the literature reporting that skin tags are most often found in intertriginous areas (e.g., axillae, neck, eyelids).

In the study by Sari et al [10], achrochordons were detected on the neck in 68.1% patients, on the back of the upper body in 26.5% patients, in the axillae in 20.4% patients and on the extremities in 5.3% patients. Hence, the initial sites to be examined for the

presence of achrochordons are the neck and axilla followed by the other sites. The possible explanation is that, in these areas there is more liability of skin to skin or skin to clothes friction in intertriginous sites. In conjunction with increased end levels of insulin like growth factors, it is likely that perspiration and friction may be necessary predeterminants for lesions.

In our study we noted a high incidence of acanthosis nigricans in patients (69%). Bhargava et al [8] observed only 12% patients showing acanthosis nigricans had skin tags. Majority patients in our study were either overweight or obese and acanthosis nigricans has a significant association with obesity and hence we imply that acanthosis nigricans may be used as a surrogate marker in predicting onset of skin tags in obese patients.[11]

In our study, 44% patients had 5 to 10 achrochordons. Similar findings were noted by Shrestha et al [12] in which number of achrochordons in individual patient showed maximum number between 5-10 in 49% of cases, followed by more than 10 in 7.8% cases.

In our study, we noted fasting glucose levels more than 100 in 44 patients, out of which 34 patients belonged to prediabetic group (100-126 mg/dL). Kahana et al [13] also observed impaired glucose tolerance in 34.3% of 216 patients with achrochordons. Based on this we state that skin tags are associated with impaired carbohydrate metabolism in a number of cases, and may serve as means for identifying patients at increased risk of having diabetes mellitus.

Median value of fasting insulin levels in our study was 18.63 while it was 9.3 in a study by Tamega et al. [14] Kurtipek et al [4] observed a median of 12.61 in a study population of 102 patients. The proliferation of fibroblasts that occurs in skin tags seems to occur secondary to hyperinsulinemia, via activation of the insulin-like growth factor (IGF-1) receptors present on their surfaces. Skin tags are closely related to fasting insulin levels.[15]

HOMA-IR values equal or more than 2.5 signified insulin resistance in our study. 81 out of 100 patients were seen to have positive results. Safoury et al [16] and Elwahab et al [17] noted in their studies that 55% and 47.9% of patients respectively, had insulin resistance. This may be explained by the fact that we did not exclude diabetics from our study (who are expected to be more insulin resistant as compared to the general population). Secondly, the subset of housewives and people with sedentary lifestyle constituted a significant number of our study group. Lack of awareness towards healthy lifestyle in our area could be another possibility. Lastly, it may also be attributed to the different cut-off values used for HOMA-IR by various authors. Tamega et al [14] used a cut-off value of 3.8 whereas other authors and in our study a value of 2.5 was used as the cut off.

In our study, the most common age group in patients with HOMA-IR more than 2.5 was 31 to 40 years (39.5%) followed by 41 to 50 years (29.6%) and 18 to 30 years (19.8%). HOMA-IR more than 2.5 in the age group of 31 to 40 years was found to be statistically significant (P value = 0.011).

In our study, progression in size of lesion was higher in patients with HOMA-IR more than 2.5 (81.5%) as compared to patients with HOMA-IR less than 2.5 (31.6%) (P value – 0.0001). This was a significant finding and from this we infer that increase in size of skin tags should be treated as a warning sign for insulin resistance.

In our study, majority of patients with HOMA-IR more than 2.5, had 5-10 achrochordons (44.4%). There was statistically no significant difference between number of achrochordons and HOMA-IR level (P value – 0.542). This was similar to the findings of Elwahab et al [17], who noted 84.78% patients to have HOMA-IR more than 2.5 and 8 or more skin tags.

In our study, most patients with HOMA-IR more than 2.5 had fasting insulin value more than 25 in 58% patients. There was a statistically significant difference between fasting insulin and HOMA-IR level (P value – 0.001). This significant correlation was not noted with fasting glucose levels and HOMA-IR level. This proves that fasting insulin levels are better predictors of insulin resistance than fasting glucose levels.

CONCLUSION

While acrochordons are usually benign and in general their presence is not a harbinger of more serious underlying conditions, however occasionally can be associated with serious underlying conditions and therefore it is important to keep these associated diseases in mind. This is especially true when encountering the obese patient presenting with the sudden and rapid development of multiple acrochordons. Although there have been plenty of studies from the West reporting an association of skin tags and insulin resistance, there are no large scale Indian studies evaluating Asian patients. The present study was an endeavour in this regard. There is a scarcity of population-based studies characterizing skin tags, their clinical and laboratory features, natural history, prognostic factors and their possible ethnic and cultural idiosyncrasies.

It is important to investigate the significance of skin tags in the different areas of the body, to assess their differences in number and color, and to evaluate the effect of therapies for IR (pharmacological or otherwise) in their genesis. In the present study, we were successful in establishing a correlation between insulin resistance and skin tags which was statistically significant. We may propose that skin tags may be one of the important skin markers of metabolic disorders and may attract physicians and dermatologist for further investigation as it is proved to be not just a cosmetic problem.

REFERENCES

1. Lee Ja, Khodae M. Enlarging, pedunculated skin lesion. Acrochordon. *AmFam Physician*. 2012 jun 15;85(12): 1191-2.
2. Bologna JL, Jorizzo JL, Rapini RP. Neoplasm of skin. *Dermatology*, 2nd ed. 2008; Section 18: 1813.
3. ShahR, Jindal A, Patel NM. Acrochordons as a cutaneous sign of metabolic syndrome: a case-control study. *Ann Med Health Sci Res*. 2014 mar-apr; 4(2):202-205.
4. Kurtipek GS, Duran C, Kutlu O, Ataseven A, Akyürek FT, Kurku H, Elmas H. The frequency of metabolic syndrome in patients with acrochordons. *Bangla J Med Sci*. January'17;16(1): 35-41
5. Srivastava A, Khare AK, Gupta LK, Mittal A, Mehta S, Balai M, Bharti G. A clinicoepidemiological study of skin tags and their association with metabolic syndrome. *Przegl Dermatol*.2017;104: 1–8
6. Abdallah SSM, Attia AS, Osman WM, El Gendy MA. Skin tags: A link between lesional mast cell count/tryptase expression and obesity and dyslipidemia. *Indian J Dermatol*,2013; 58(3):240-240
7. Maluki AH, Abdullah AA. Metabolic associations with skin tags. *Int J DermatolClin Res*.2016; 2(1):003-011.
8. Bhargava P, Mathur SK, Mathur DK, Malpani S, Goel S. Acrochordon, diabetes and associations. *Indian J DermatolVenereolLeprol*. 1996; 62: 226-228.
9. Mustafa NAO,Rahaman AM, Ramadan A,Alfarouk KO, Aljarbou A,Elhassan GO,Muddathir AK, Bashir IA,Halloul AE, Bashir AHH..Skin tags and atherogenic lipid profile in diabetes mellitus type 2 in Jabir abueliz diabetes center,American J DermatolVenereol2017; 6(3): 41-50
10. Sari R & Ayse A & Erkan A & Mustafa B. The metabolic profile in patients with skin tags. *ClinExp Med*. 2010;10: 193–197
11. Sivakumar S, Banupriya K. A cross-sectional descriptive clinical study of dermatological manifestations in obesity. *Int J Res Dermatol*,2017;3: 337-41
12. Shrestha P, Poudyal Y, Rajbhandari SL. Acrochordons and diabetes mellitus: A Case control study. *Nep J DermatolVenereolLeprol*, Jan. 2016;13(1): 32-37
13. Kahana M, Grossman E, Feinstein A, Ronnen M, Cohen M, Millet MS. Skin tags: a cutaneous marker for diabetes mellitus. *ActaDermVenereol*. 1987;67(2): 175-7.
14. Tamega AA, Pinheiro AAM, Massaki GM. Association between skin tags and insulin resistance. *An. Bras. Dermatol*. 2010 feb; 85(1): 25-31.
15. Barbato MT. Association of acanthosisnigricans and skin tags with insulin resistance *AnaisBrasileiros De Dermatologia* · may 2013
16. El Safoury OS, Abdel HR, Fawzy MM, Kadry D, Amin IM, Om AZ, et al. Skin tags, leptin, metabolic syndrome and change of the life style. *Indian J DermatolVenereolLeprol* 2011;77: 577-80.
17. Elwahab MAA,Osman LA and Morsi AN. Association between skin tags and insulin resistance in khartoum state. *Eur J Biomed Pharma Sci*.2017; 4(3)